



Historical autopsy: A contribution to the investigation of State terrorism crimes in Uruguay

Hugo Rodríguez Almada ^{*,1}, Frances Borches Duhalde ²

Department of Legal Medicine and Forensic Sciences of the Medical School of Universidad de la República, Uruguay

ARTICLE INFO

Keywords:

Historical autopsy
Humanitarian forensic action
State crime
Human Rights

ABSTRACT

Historical autopsy has been defined as the forensic investigation of the cause, manner and circumstances of a death bearing historical, humanitarian or judicial interest, based on the systematization and interpretation of the available information provided by documents and testimonies, when there was no direct access to the corpse or skeletal remains. Its purpose is getting closer to the truth or, at least, discarding some hypotheses or versions. Four paradigmatic cases of political violence in Uruguay that occurred in the 1970s are reported. In all of them, the historical autopsy demonstrated the falseness of official versions and significantly contributed to prove the criminal responsibility of State agents. Three of them correspond to deaths that occurred in the context of torture and the fourth to a military operation with multiple victims. In addition to contributing to court decisions, the psychosocial benefit of clarifying the facts surrounding human rights violations is well known from the perspective of humanitarian forensic action. As with any forensic investigation technique, it requires knowledge of both its scope and limitations.

1. Introduction

Etymologically, the term autopsy means to see for oneself. Applied to Forensic Sciences, it refers to the postmortem examination of the body with the purpose of investigating the cause and manner of death [1]. By extension, the term autopsy is applied to other techniques, such as psychological autopsy, molecular autopsy or virtual autopsy [2–4].

In some cases, forensic medical examiners do not have access to the corpse or its skeletal remains. Even then it is possible to recover documents and obtain witness accounts that allow us to get closer to the truth or, at least, to rule out some hypotheses or versions. The historical autopsy method is based on the systematization of this information for its subsequent forensic interpretation, aimed at determining the cause, manner, and circumstances of death.

The method was described in 2003 in a joint publication of Universidad de la República (Uruguay) and Universitat de València (Spain) which reported the solving of a crime of political violence with multiple victims that had taken place in Uruguay in 1972 [5].

Historical autopsy has been defined as the forensic investigation of the cause, manner and circumstances of a death bearing historical,

humanitarian or judicial interest, based on the critical, harmonic, hierarchical and objective interpretation of the available information provided by documents and testimonies, when there was no direct access to the corpse or skeletal remains. As with any forensic investigation technique, it requires knowledge of both its scope and limitations [5].

It was first used in cases of historical interest or for humanitarian purposes at the request of the victims' relatives [5,6]. Furthermore, in accordance with the Rome Statute of the International Criminal Court, which sets forth the non-applicability of statutes of limitations regarding crimes against humanity, Uruguayan prosecutors' offices and courts continue to investigate crimes of this type that occurred in the 1970s and 1980s, and frequently request historical autopsy reports as expert evidence.

In Uruguay, Law No. 18.596 (2009) defined State terrorism as "the violation of a Rule of Law State that prevents people from exercising their fundamental rights, contravening Human Rights or the rules of International Humanitarian Law, during the period from June 27, 1973 to February 28, 1985".

Once the period of State terrorism ended, several complaints were filed for acts of torture, homicide and enforced disappearance. Criminal

* Corresponding author.

E-mail address: hrodriguez@fmed.edu.uy (H. Rodríguez Almada).

¹ <http://orcid.org/0000-0002-7330-6508>.

² <http://orcid.org/0000-0002-4759-3830>.

<https://doi.org/10.1016/j.fsir.2021.100242>

Received 24 August 2021; Received in revised form 20 October 2021; Accepted 25 October 2021

Available online 1 November 2021

2665-9107/© 2021 The Author(s).

Published by Elsevier B.V. This is an open access article under the CC BY-NC-ND license

(<http://creativecommons.org/licenses/by-nc-nd/4.0/>).

proceedings were paused for long periods of time, either because of the domestic law that prevented investigations or due to delaying strategies by defendants.

In 2007, the justice system requested, for the first time, that an historical autopsy be carried out in the case of a young woman who died in custody at a military facility known to be a detention and torture site (Nibia Sabalsagary case). Since then, dozens of such reports have been requested. Most of them were commissioned to the working team of the Department of Legal Medicine and Forensic Sciences of the Medical School of Universidad de la República, sometimes they were carried out by forensic medical examiners of the Judiciary and, in other cases, by professionals from both institutions working together [5,7].

These cases investigated through the historical autopsy methodology correspond to potentially unlawful deaths caused by acts or omissions of the State in any of the forms defined by the Minnesota Protocol:

- (a) Deaths caused by law enforcement officials or other agents of the State; or by paramilitary groups, militias or “death squads” suspected of acting under the direction of the State or with its permission or acquiescence; and deaths caused by private military or security forces exercising State functions.
- (b) Deaths occurring while the person was detained by, or was in the custody of, the State, its bodies or agents. This includes, for example, all deaths of persons detained in prisons, in other places of detention (official and/or otherwise) and in other facilities where the State exercises heightened control over their lives.
- (c) Deaths occurring as a consequence of the State’s failure to meet its obligations to protect life [8].

In many of these deaths, the forensic investigation did not prove the occurrence of the reported crimes through the historical autopsy, and in others it was concluded that they were probably due to natural causes (non-violent), with no intent or negligence by the State. But in other cases, historical autopsies have demonstrated, based on documents from the military authorities of the time, the falseness of official versions and the truthfulness of the accusations made by the victims’ families. In these cases, conclusions were based on the regular forensic practice criteria, as well as on international standards for the investigation of human rights violations [8–11].

2. Purposes

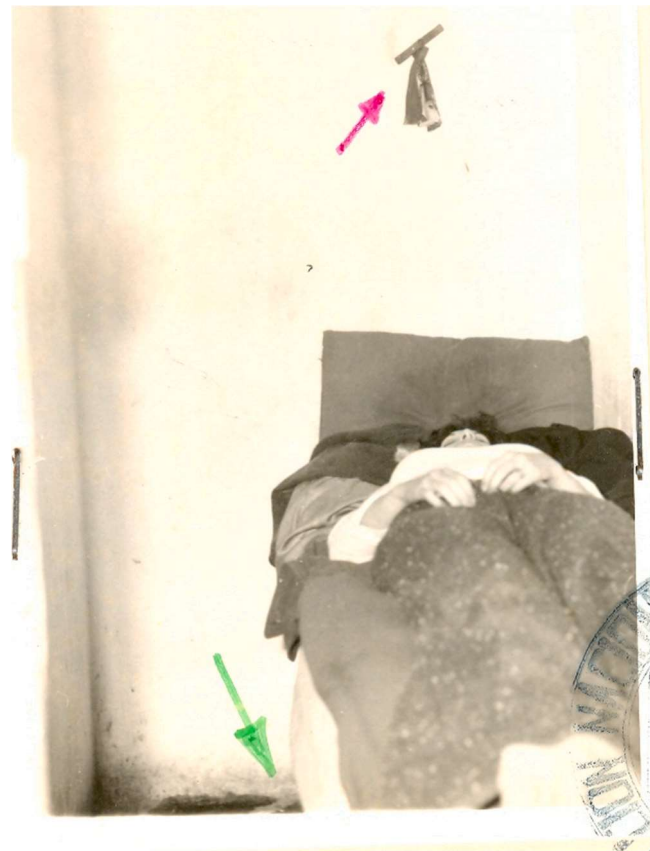1. Make known the contribution of Forensic Medicine to the investigation of crimes against humanity in Uruguay during the period of State terrorism (between June 27, 1973 and February 28, 1985) through the historical autopsy method.
2. Inform of some paradigmatic cases in which the results of the historical autopsy significantly contributed to prove the criminal responsibility of State agents in crimes against humanity.

3. Methodology

A selection was made of State terrorism crimes committed in Uruguay, in which historical autopsies were carried out to solve the cases, meeting the following two requirements:

- (a) That, from the forensic point of view, the historical autopsy allowed achieving positive results for the resolution of the case.
- (b) That the report has been acknowledged as a relevant means of evidence by the justice system, its conclusions having been included by the prosecutor as substantive grounds for the accusation or having been mentioned in the court decision.

All the information mentioned in each case was provided by the authority that requested the expert report, and it included the historical research of the Universidad de la República on the recent past, the Final Report of the *Comisión para la Paz*



Photograph 1. Photograph of the crime scene. The victim’s body, the ligature point and the neck scarf used for the suicide, according to the official version of the time, can be seen.

(Commission for the Peace), the records of the victims of State terrorism provided by the *Secretaría de Derechos Humanos para el Pasado Reciente de la Presidencia de la República* (Secretariat of Human Rights for the Recent Past of the Presidency of the Republic of Uruguay) and the court files of each of the cases studied [12–16]. These documents, as well as the court files of the cases included in this paper, are available for the public to access.

The presentation of each case is organized into four items:

- (a) Undisputed facts: facts plausible from a medico-legal point of view and regarding which there are no contradictory historical or judicial versions.
- (b) Disputed facts: facts regarding which there exist different versions.
- (c) Forensic conclusions.
- (d) Their impact on the judicial system (prosecutors’ opinions, lower courts’ decisions, final (non-appealable) decisions).

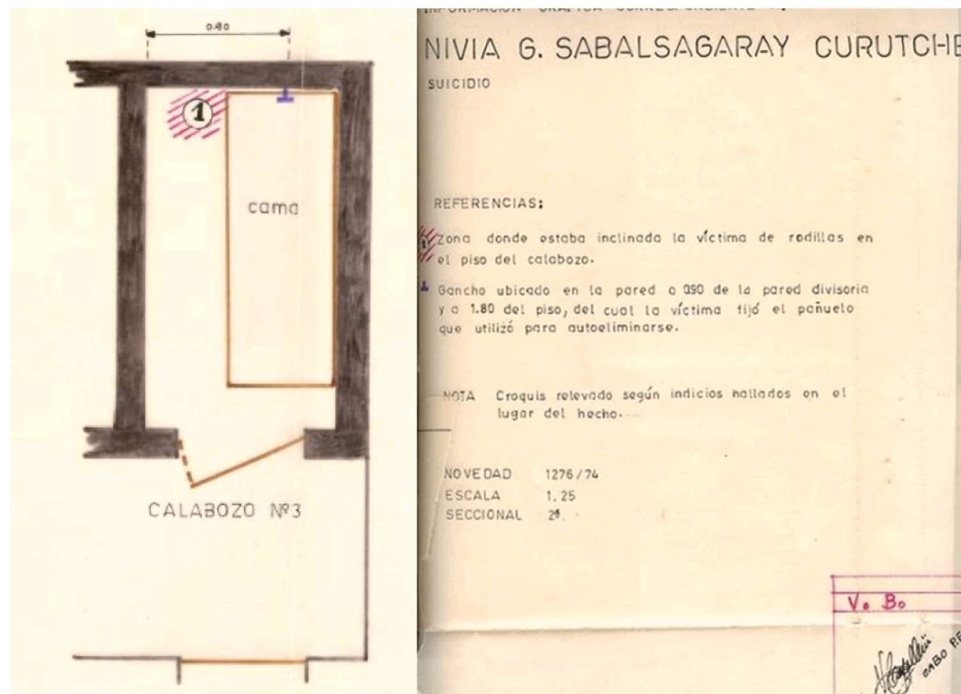
4. Presentation of cases

4.1. Case 1. Nibia Sabalsagary Curutchet

4.1.1. Undisputed facts

In the early morning of September 29, 1974, 24-year-old Nibia Sabalsagary Curutchet was arrested at her home in Montevideo by government agents and taken to a military unit that was used as an interrogation center for political prisoners. In the afternoon of that same day she was reported dead in a cell. The Military Justice system investigated the matter and concluded it was a case of suicide by hanging.

When the period of State terrorism was over, the victim’s family filed a criminal complaint for homicide.



Photograph 2. Planimetry of the crime scene where it is documented that the ligature point of the noose was located 180 centimeters from the floor.

4.1.2. Conflicting versions

The official version at the time was that the young woman was being held in a cell awaiting interrogation and was found dead by an Army officer. According to him, the victim was in partial suspension with a neck scarf around her neck and her knees on the floor. The autopsy report by a military pathologist described an interrupted ligature mark in the nape region, 3–5 centimeters wide, with abrasions. The internal examination described: right atrial enlargement and pulmonary congestion, as well as foci of hemorrhage in the thyroid region. The military pathologist certified that death was due to suicidal hanging with a rope. In a later statement he corrected himself and stated that she had a twisted stocking around her neck.

Witnesses supporting the criminal complaint said that the victim died while being interrogated under a torture method known as dry-boarding (plastic bag suffocation).

4.1.3. Historical autopsy

The documents of the official investigation carried out at the time by the Military Justice system, including a photographic survey, the planimetry of the crime scene, and the autopsy report practiced by a military pathologist that included no photographs were all used for the forensic report. Testimonies of other prisoners, who were in the same military center at the time of the young woman's death, were also used for the report.

The most objective elements available were the photographs of the place of the event and the planimetric survey carried out by the Scientific Police Division. [Photograph 1](#) show the corpse on the bed (which was not the original position, according to both versions). On the neck, an image compatible with a furrow such as the one produced by a soft ligature, can be observed. There is also a neck scarf cut off that would have been used for body suspension. The image shows an iron element on the wall used as a lock for the folding bed, where the scarf would have been tied. [Photograph 2](#) shows that the iron element was at a height of 180 cm.

From the critical analysis of all available elements, it was confirmed that it had been a violent death, with signs of asphyxia and violence on the neck. The manner of death could not be determined with certainty. Although suicide could not be ruled out, the findings were consistent

with the version of a death by the dry-boarding torture method. Indeed, the stigmata on the neck skin are consistent with hanging, but also with the compression exerted during dry-boarding. The same can be said of the non-specific internal findings of asphyxia. The hemorrhages described in the thyroid region were not expected for hanging, but could correspond to the violence exerted during such torture method.

Upon analyzing the documents of the crime scene survey, it was outwardly ruled out that the victim could have been in partial suspension with her knees resting on the ground, if the ligature point was 180 centimeters high (considerably higher than the victim's height) and the ligature used had the dimensions of a neck scarf, as documented by the Scientific Police Division.

4.1.4. Conclusions of the court

On April 29, 2013, the Criminal Trial Court Term No 10 found the officer responsible for interrogating prisoners and the Head of the military unit guilty of homicide under especially aggravating circumstances and sentenced to 28 years in prison. Both court decisions were confirmed by the Court of Appeals.

It was the first case in Uruguay in which a historical autopsy was requested as evidence for a criminal trial.³

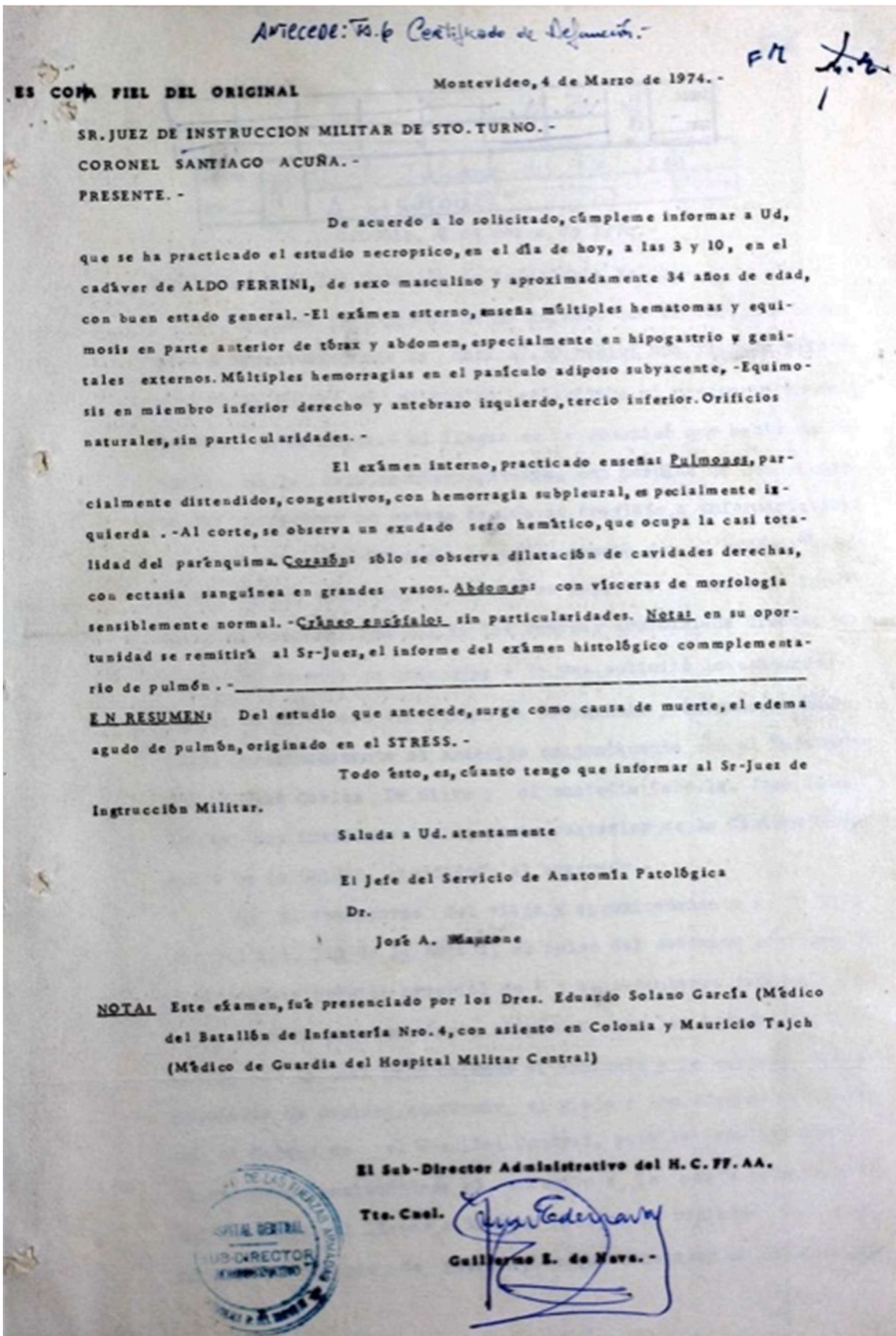
4.2. Case 2. Aldo Perrini Guala

4.2.1. Undisputed facts

Aldo Perrini was arrested at his place of work in the city of Carmelo, on February 26, 1974, and taken to a military facility that was used as a detention and interrogation center for political prisoners. On March 3, 1974, he lost consciousness during an interrogation. The investigation carried out by the Military Justice system concluded that it had been a natural death caused by stress, and the case was closed.

When the period of State terrorism ended, Perrini's family filed a criminal complaint asserting that it had been a violent death caused by torture.

³ Court File IUE 97-397/2004: "Sabalsagaray, Nibia. Su muerte".



Photograph 3. Image of the autopsy report describing the macroscopic injuries on Aldo Perrini's corpse.

AUTECED: 17.5. Copia of 80/74-52. Fº 6

CERTIFICADO DE DEFUNCION

Nº 497223

REPUBLICA ORIENTAL DEL URUGUAY
MINISTERIO DE SALUD PUBLICA
DEPARTAMENTO DE ESTADISTICA

NO MRES Y APELLIDOS DEL FALLECIDO ALDO PERRINI

A. LUGAR DE LA DEFUNCION		B. RESIDENCIA HABITUAL DEL FALLECIDO
1. Departamento <u>Montevideo</u>	2. Sección Judicial <u>19a</u>	1. Departamento <u>Montevideo</u>
3. Ciudad, pueblo o paraje <u>Ciudad</u>	4. Anótese si la ubicación es urbana, suburbana o rural <u>Urbana</u>	2. Sección Judicial <u>19a</u>
5. Dirección <u>8 de octubre 3020</u>	6. Si la defunción ocurrió en un establecimiento asistencial público o privado, anótese: <u>Hospital Militar</u>	3. Ciudad, pueblo o paraje <u>Ciudad</u>
7. Dirección <u>8 de octubre 3020</u>	7. Fecha en que habla ingresado en ella: día <u>17</u> mes <u>3</u> año <u>74</u>	4. Anótese si la ubicación es urbana, suburbana o rural <u>Urbana</u>

C. DATOS PERSONALES DEL FALLECIDO		7. PROFESION U OCUPACION
1. Sexo <u>masculino</u>	2. Raza <u>Blanca</u>	a. En el período inmediato anterior a la muerte <u>Medico</u>
3. Fecha en que habla nacido: día <u>17</u> mes <u>3</u> año <u>1924</u>	4. Estado Civil <u>casado</u>	b. Habitual al difiere de la anterior <u>Medico</u>
5. EDAD AL FALLECER		c. Si lo anotado en el renglón "a" representa un estado de inactividad (como ser jubilado, Pensionista, etc.) anótese la profesión, ocupación u oficio que habitualmente desempeñaba en su época de actividad <u>Medico</u>
SI HABIA VIVIDO		d. Tipo de comercio o industria a que estaba afectada su actividad <u>Medico</u>
a. Más de 1 año	b. Menos de 1 año	
D. CERTIFICADO MEDICO		
1. La defunción que se certifica ocurrió el día <u>17</u> del mes <u>marzo</u> del año 19 <u>74</u> a la hora <u>11</u> y <u>30</u> minutos		2. Tiempo aproximado entre el suceso y la muerte <u>11:30</u>
PARTE I: ESTADO O ENFERMEDAD CAUSANTE DIRECTO DE LA MUERTE		
No se refiere a la forma como sobrevino la muerte (por ejemplo: Desfallecimiento cardíaco, Asfexia, etc.), sino que lo que se debe anotar es la enfermedad, lesión o complicación que causó la muerte.		
A) <u>Edema agudo pulmonar</u>	DEBIDO A (O COMO CONSECUENCIA DE):	
B) <u>Stress</u>	DEBIDO A (O COMO CONSECUENCIA DE):	
C) <u>DEBIDO A LA CORONA</u>	DEBIDO A (O COMO CONSECUENCIA DE):	
CAUSAS QUE PRECEDIERON:		
Anótese cualquier proceso morbido que haya dado lugar a la causa mencionada en A, estableciéndose en último término la causa inicial de las que condujeron a la muerte.		
PARTE II: OTROS ESTADOS MORBIDOS CONTRIBUYENTES:		
Anótese cualquier estado o proceso que haya contribuido a la muerte, pero que no está relacionado con la causa inmediata, anotada en A)		
6. Si la muerte se debió a factores externos, se debe establecer:		
a. Suicidio: <u>Describese el o los medios usados</u>	a. Si se habla practicado, alguna intervención, déjese anotado en "PARTE I" o en "PARTE II" según corresponda (Items 2, 3, 4 o 5 precedentes) su papel en la producción de la muerte. Además:	
b. Homicidio: <u>Describese el o los medios usados</u>	a. día <u>17</u> mes <u>3</u> año <u>74</u>	
c. Accidente: <u>Describese el tipo de accidente, las circunstancias y el lugar</u>	b. Nombre de la intervención:	
7. Fecha: día <u>17</u> mes <u>3</u> año <u>74</u>	c. Causa por la que se operó:	
	8. Si se practicó autopsia describense sus hallazgos.	
1. El que suscribe: <u>Jose A. Mouton</u> en su carácter de <u>Medico</u>		
2. domiciliado en: <u>Localidad</u> <u>Calle</u> <u>Número</u>		
3. Día <u>17</u> de <u>Marzo</u> de 19 <u>74</u> tienen valor de declaración jurada. Firma <u>Jose A. Mouton</u>		
4. Cuando la defunción sea certificada en el ejercicio privado de la profesión, en este lugar se debe colocar e inutilizar el timbro que establece la Ley 12.125 de 23 de Agosto de 1954 (Caja de Jubilaciones y Pensiones de Profesionales Universitarios)		
5. Cuando la defunción haya ocurrido en un establecimiento público asistencial o de internación debe ponerse el sello correspondiente en este espacio		
7. El Oficial del Registro del Estado Civil de la Sección Judicial del Departamento de <u>Montevideo</u> hace constar que en el acta <u>de la fecha</u>		

Photograph 4. Image of Aldo Perrini's death certificate stating that he died of "stress".

NY 555303

**DIVISION HIGIENE
DEPARTAMENTO DE ESTADISTICA**

NOMBRES Y APELLIDOS DEL FALLECIDO Iván Morales Generali

A. LUGAR DE LA DEFUNCION		B. RESIDENCIA HABITUAL DEL FALLECIDO	C. DATOS PERSONALES DEL FALLECIDO	D. PROFESION U OCUPACION
1. Departamento 2. Sección Judicial 3. Ciudad, pueblo o paraje 4. Anótese si la ubicación es urbana, suburbana o rural 5. Dirección 6. Si la defunción ocurrió en un establecimiento asistencial público o privado, anótese: 7. Dirección		1. Departamento 2. Sección Judicial 3. Ciudad, pueblo o paraje 4. Anótese si la ubicación es urbana, suburbana o rural 5. Dirección 6. Si el fallecido era un asilado o recluso de alguna institución, anótese: 7. Fecha en que habió ingresado en ella: día mes año	1. Sexo 2. Raza 3. Nombre del país en que nació 4. Fecha en que habió nacido 5. Estado Civil 6. EDAD AL FALLECER 7. SI HABIA VIVIDO	1. En el período inmediato anterior a la muerte 2. Habitual si difiere de la anterior 3. Si lo anotado en el renglón "a" representa un estado de inactividad (como ser Jubilado, Pensionista, etc.) anótese la profesión, ocupación u oficio que habitualmente desempeñaba en su época de actividad 4. Tipo de comercio o industria a que estaba afectado su actividad

D. CERTIFICADO MEDICO

1. La defunción que se certifica ocurrió el día del mes del año 19..... a la hora y minutos

2. **PARTE I:**

3. **ESTADO O ENFERMEDAD CAUSANTE DIRECTO DE LA MUERTE:**
 No se refiere a la forma como sobrevino la muerte (por ejemplo: Desfallecimiento cardiaco, Astenia, etc.), sino que lo que se debe anotar es la enfermedad, lesión o complicación que causó la muerte.

4. **CAUSAS QUE PRECEDIERON:**
 Anótese cualquier proceso morbido que haya dado lugar a la causa mencionada en A, estableciéndose en último término la causa inicial de las que condujeron a la muerte.

5. **PARTE II:**
OTROS ESTADOS MORBIDOS CONTRIBUYENTES:
 Anótese cualquier estado o proceso que haya contribuido a la muerte, pero que no esté relacionado con la causa inmediata, anotada en A)

6. Si la muerte se debió a factores externos, se debe establecer:

a. Suicidio:
 b. Homicidio:
 c. Accidente:

7. Fecha: día mes año

8. Si se había practicado, alguna intervención, déjese anotado en "PARTE I" o en "PARTE II" según corresponda (Ítems 2, 3, 4 o 5 precedentes) su papel en la producción de la muerte. - Además:

a. día mes año y
 b. Nombre de la intervención
 c. Causa por la que se operó:
 d. Si se practicó autopsia describáse sus hallazgos:

9. El que suscribe: JOSE A. MAJONE en su carácter de Medico
 Nombre y apellidos en caracteres legibles (preferentemente escrito a máquina y con letra de imprenta)
 Analista de título que lo autoriza a firmar este certificado

10. domiciliado en: Localidad Calle Número
 establece que los datos mencionados en el presente certificado, que suscribe

11. de de 19..... tienen valor de declaración jurada. Firma [Firma]

Photograph 5. Death certificate of Iván Morales signed by the military pathologist attributing his death to suicide by likely poisoning.

4.2.2. Conflicting versions

The official version at the time, and that of the accused military officers, indicates that Perrini was excited, violent and he was banging his head against the wall. The testimonies of the military officers agree in that detainees were subjected to a “rigorous,” “energetic,” “harsh” or “demanding” treatment. They also acknowledged that prisoners were kept blindfolded, restrained with ropes or handcuffs, and forced to stand for long periods of time.

They held that Perrini had been taken to the “interrogation room” and lost consciousness. Despite having been quickly assisted by the doctor of the military unit, he died, and an autopsy was performed at the Military Hospital. The military pathologist reported: “Good general condition;” “multiple hematomas and ecchymosis in the anterior part of

the thorax and abdomen, especially in the hypogastric region and external genitalia;” “multiple bleedings in the intradermal bruises;” “ecchymosis in the right lower limb and left forearm, lower third.” Regarding the internal examination, he reported: “Partially hyperinflated lungs, congestive, with subpleural bleeding, especially on the left. Serosanguineous fluid occupying almost the entire parenchyma is observed in section.” “Heart: only enlargement of the right chambers is observed, with blood ectasis in large vessels.” He established that the cause of death was “acute pulmonary edema, caused by stress.” During the autopsy, samples of the lungs were collected for histopathological study by the same pathologist, who reported: “areas of node bleeding, with blood pigment phagocytosis,” “compensating emphysema;” “congestion,” “edema” and “in some sectors, air sacs with serofibrinous

fluid.” He concluded that it corresponded to “stressed lung” (Photographs 3 and 4).

The version of those who reported the crime, supported by former political prisoners of the time, indicates that Perrini was especially tortured, subjected to various torture methods such as forced standing, waterboarding, and cruel beatings.

4.2.3. Historical autopsy

Based on the undisputed fact that Aldo Perrini died in custody and in the context of the torture methods used with political prisoners at the time in that military detention center, it was possible to demonstrate that the external injuries described in the autopsy report (ecchymosis and hematomas on the limbs, trunk, especially noticeable in the hypogastric region and external genitalia) were consistent with a victim who had suffered multiple beatings. This is to be expected in the context of torture reported by former prisoners and euphemistically admitted by military officers who were at the scene. Contusions were of great intensity, capable of producing hematomas in very resistant parts, such as the anterior wall of the abdomen. Injuries found on the limbs are suggestive of a defensive nature. The extensive lesions in the hypogastric region and external genitalia indicate aggressions aimed at causing severe pain. The findings in connection to the lungs described in the autopsy and in the histopathological examination are compatible with an incomplete submersion, such as the one occurring in the waterboarding method of torture (to which Perrini was subjected according to those reporting the crime).

The manner of death was clearly established as a violent death, provoked by different means, under torture.

The cause of death could not be established with absolute certainty, there being two plausible compatible hypotheses:

- a) Beaten to death. The findings reveal repeated aggressions with blunt objects, which are in themselves effective to cause death by different mechanisms, such as reflex inhibition to painful stimuli, hypovolemic shock (due to splenic sequestration or internal bleeding), brain distress or fat embolism.
- b) Heart failure due to drowning during waterboarding. Although pulmonary findings are very significant, they could be due to waterboarding sessions prior to the death (the presence of phagocytized blood pigment indicates a survival period between the alveolar hemorrhage and death).

The existence of injuries of different dates caused by different mechanisms allows us to think that the victim was subjected to various methods of torture during several days. This corresponds to the period of time between his detention and death, and supports the witnesses' testimonies.

4.2.4. Conclusions of the court

In 2015 two of the Army officers who interrogated Perrini at the time of his death (a third officer had died by then) were prosecuted with imprisonment as perpetrators of the homicide; one of them committed suicide upon learning of the court decision and the other was sentenced to 22 years in prison. The judgment became firm and final in 2019, after successive appeals filed with the Court of Appeals and the Supreme Court of Justice.⁴

4.3. Case 3. Iván Morales Generalli

4.3.1. Undisputed facts

According to the military record of the time, Iván Morales Generalli was arrested on November 21, 1974 at approximately 5 p.m. and taken to a military facility.

Between 5:30 and 6:15 p.m. on the same day of the arrest, the detainee was interrogated by officers of the *Órgano Coordinador de Operaciones Anti-Subversivas* (OCAO, Coordinating Body for Anti-Subversive Operations).

The only available photograph of the corpse, prior to the autopsy, shows abrasions in the mental region. The rest of the body surface area is not shown or is covered by clothing.

4.3.2. Conflicting versions

According to the Military Judge in the case, he received a call from the Head of the military center to inform him that “the seditious detainee Iván Morales had died while being interrogated in said center.”

Another of the officers in charge of the detention center testified that, at approximately 7:00 p.m., the two interrogating officers of the OCAO “proceeded to resume the interrogation, noting that the seditious person in question was unconscious and apparently dead.” The officer testified that between 6:15 and 7:00 p.m. on November 21, 1974, Iván Morales was kept in a cell which was being guarded from the outside.

The autopsy report performed by the military pathologist stated:

- a) External examination: abrasions on the face, thorax, anterior wall of the abdomen and posterior face of the thigh, as well as on the left lumbar region. The report also indicated “linear abrasions on both wrists.”
- b) Internal examination: lungs “with multiple subserosal microbleeds.” Heart with enlarged right chambers. A “muco-hematic” gastric content is described. The report highlights the purplish coloration of the lungs, liver, spleen and stomach.

With these findings, the pathologist initially certified the following as cause of death: “Poisoning (probable)” and, as manner of death, “suicide” (Photograph 5).

He requested toxicological tests for “cyanide, metals, alkaloids and barbiturates” in liver, spleen and gastric contents, all of which were negative.

The pathologist himself performed histopathological studies of the lungs, liver, kidney, heart and central nervous system, and he concluded the diagnosis of “fat embolism” (.) “diffuse” (Photograph 6).

With this result he modified his initial autopsy diagnosis and attributed death to “sudden death” due to fat embolism. He suggested that the “diffuse fat embolism could have been originated in the hematoma of the perinephric fat.”

The case was closed by the Military Justice system.

4.3.3. Historical autopsy

Only the documents of the official investigation carried out at the time of the events by the Military Justice were available.

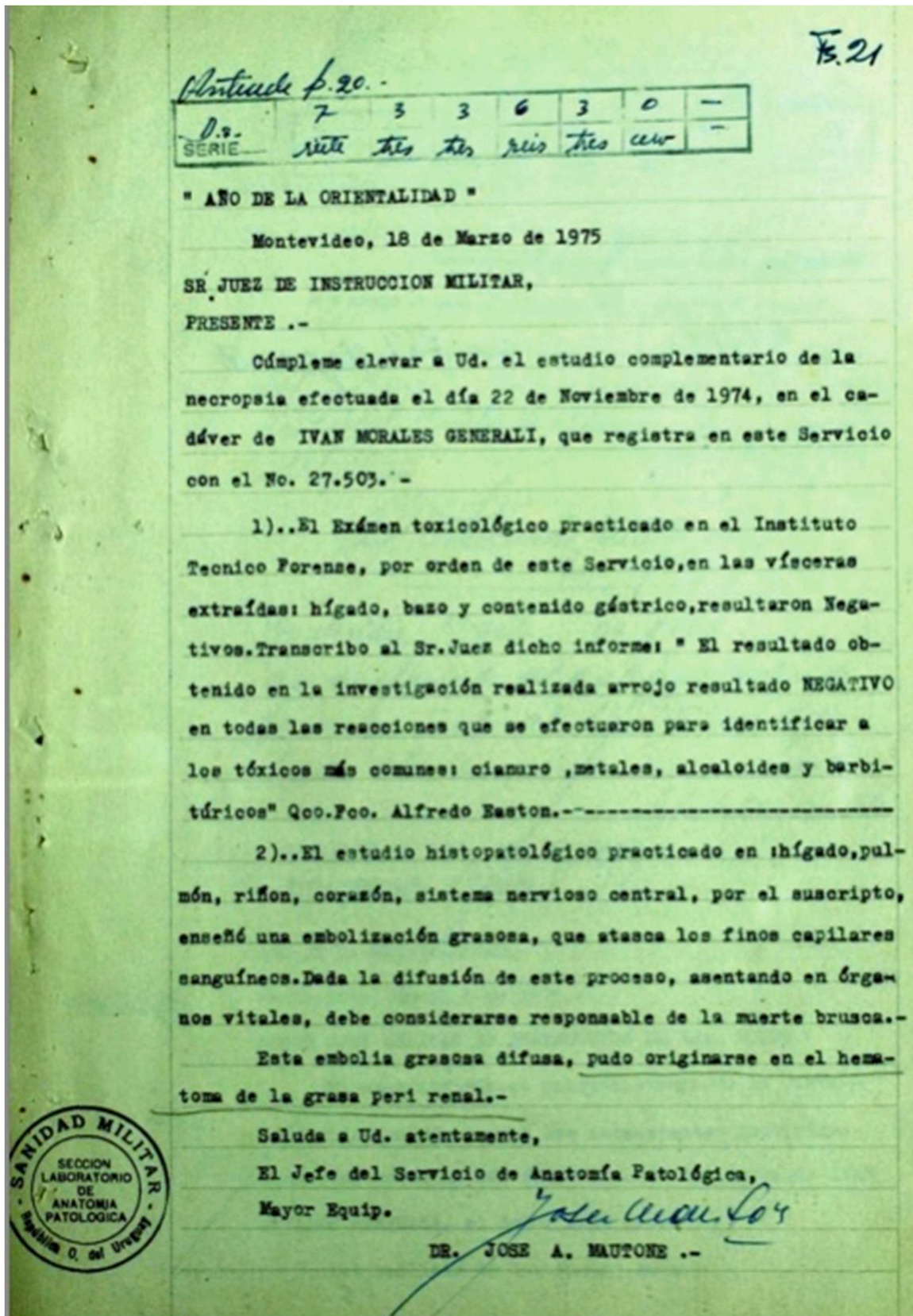
The historical autopsy proved that Iván Morales Generalli died while being held in custody in the context of interrogations carried out by OCAO officers in the military facility.

His death occurred in the afternoon of November 21, 1974, a few hours after being detained, either during an interrogation or in the time between two interrogation sessions (between 6:15 p.m. when the first session ended and 7:00 p.m. when the second was about to begin).

The autopsy report shows extensive open blunt injuries (abrasions) involving large areas of the body (face, limbs and trunk). In the context of the facts, these injuries to the face, trunk and lower limbs could have been inflicted by “natural weapons” (fist blows and kicks), notwithstanding the involvement of other blunt objects. The injuries to both wrists are typical of a restrained victim, either by the use of tight handcuffs or of aggressive materials such as aluminum wire.

Although the autopsy protocol omitted to describe the internal traumatic injuries, the histopathological report by the same military pathologist mentioned a “hematoma of the perinephric fat” as the origin of the diffuse fat embolism. This hematoma of the perinephric fat corresponds to the result of a high-energy trauma.

⁴ Court File IUE 2-53193/2010: “Perrini Santamaría, Nino Piero. Denuncia”.



Photograph 6. Image of the military file showing that all toxicology test results were negative; and that the histopathological study confirmed the diffuse fat embolism in relation to the hematoma of the perinephric fat.

For all these reasons, the military documents show that the corpse presented evident signs of having been repeatedly beaten prior to his death.

At the histopathological level, the findings of subpleural microbleeds described in the autopsy report and of the diffuse fat embolism are significant.

The medico-legal concordant interpretation of all available elements, assuming that the information from the military documents is true, allows us to affirm that the cause of death of Iván Morales Generalli was post-traumatic fat embolism.

In sum: in this case, there is an absolute coincidence between the external, internal and histopathological findings, which demonstrate that it was a violent death, caused by different means, being the final cause of death the pulmonary fat embolism and the underlying cause of death the multiple traumas suffered by Iván Morales Generalli, in the context of the interrogation to which he was subjected in a military center on November 21, 1974.

4.3.4. Conclusion of the court

By court decision number 302 dated March 26, 2020, the Criminal Trial Court Term No. 23 prosecuted with imprisonment one of the three officers involved in the death of Iván Morales for homicide under especially aggravating circumstances. Another officer had died by then and the third one is currently serving a sentence in Argentina for other human rights violations. The Criminal Court of Appeals confirmed the lower court's decision on September 11, 2020, under judgment number 577/2020.⁵

4.4. Case 4. Girls of April: Silvia Reyes, Laura Raggio and Diana Maidanik

4.4.1. Undisputed facts

On April 21, 1974 at 02:45 a.m., Silvia Reyes (aged 19), Laura Raggio (aged 19) and Diana Maidanik (aged 21) died inside the house of one of them in the context of an Army operation.

Captain Julio César Gutiérrez was also seriously wounded in the incident and died some days later at the Military Hospital.

All the deaths were the result of injuries caused by bullets.

4.4.2. Conflicting versions


According to the version of the military officers, the death of the three young women occurred in an armed confrontation, in which the Army soldiers responded to the attack initiated by them. They testified that the women were armed with two revolvers and a grenade.

The initial version stated that, despite having been ordered not to enter, Captain Gutiérrez entered the house and was taken down by a gunshot fired from inside the house.

As it results from the medical records of the military physicians, the multiple bullet wounds of Gutiérrez followed different directions: the wound on the neck, from right to left and from front to back; and the wound on the trunk, from right to left and from back to front. The direction was not described in the wounds on the thighs. From the above, it appears that he was shot from the right.

An autopsy was performed on the three deceased women by a military pathologist, whose reports state the following:

Silvia Reyes: two bullet entry wounds in the skull and one in the face "crater-shaped" with trajectory from right to left. At right and left shoulder and hypogastrium, she presented bullet entry wounds with a front-to-back direction. A transfixing wound on the right arm that re-entered the thorax and another wound in the left forearm were described. Internal examination: massive destruction of the brain with bursting of the skull cap and base, hemothorax due to right lung injury, intra-abdominal hemorrhage caused by the bursting of the left hepatic



Photograph 7. Photograph of the crime scene obtained from the military file.

lobe and perforation of the stomach. There is no description of the uterus in the autopsy report, but witnesses say that she was three months pregnant.

Laura Raggio: one bullet entry wound in the right maxilla and exit in the occipital region (front to back); three bullet wounds in the right arm in a front-to-back direction, one of which penetrated the thorax. One bullet entry wound in the base of the neck with exit in the left armpit; one bullet entry wound in the right hypochondriac region with exit in the right lumbar region. Internally there was massive destruction of the brain and skull, destruction of the humeral head, and hemothorax caused by perforation of the aortic arch and both lungs. The abdominal injury caused liver burst resulting in intra-abdominal hemorrhage.

Diana Maidanik: multiple gunshot wounds to the skull with entry from right to left. The transfixing wounds in the lower jaw and neck also followed a right-to-left direction. In the left shoulder the direction was front-to-back. There were also entry wounds in the middle third of the arm and in the supraumbilical region, transfixing wounds in the left thigh with a front-to-back direction, a transfixing wound in the left knee with a right-to-left direction, and a non-exit entry wound in the middle third of the right thigh. At dorsal level she had four exit wounds. The internal examination showed: marked brain destruction with bursting of the skull cap and base; and hemothorax and hemopericardium due to pulmonary and right ventricle lesions. She had small bowel loop lesions.

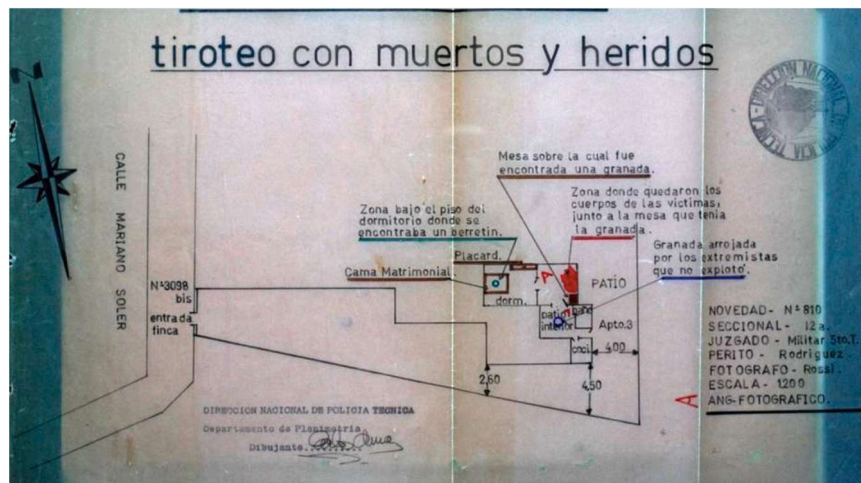
The skeletal remains of Reyes and Raggio were exhumed 41 years later by two anthropologists who reported that the injuries were caused by multiple bullets and concluded that the skull injuries were the cause of death.

In contrast to the version of the military officers, the complainants and neighbors claim that the three women were executed by the military. Some witnesses say that the women were screaming to not be killed.

4.4.3. Historical autopsy

The documents of the official investigation carried out at the time of the events by the Military Justice system were accessed, where the photographic and planimetric surveys of the Scientific Police Division are included, as well as the autopsy reports prepared by the military pathologist. The [Photograph 7](#) of the scene show the corpses of the three women stuffed against the east wall of the room and against a piece of furniture found on the south wall. There are evident injuries compatible with those caused by bullets on the three bodies as well as blood stains on the east wall, the floor, and the said piece of furniture. The injuries described by the pathologist are compatible with having been caused by automatic or semi-automatic weapon burst fire, and all of them follow a

⁵ Court File IUE 88-209/2011: "Morales Generalli, Iván. Su muerte".



Photograph 8. Planimetry of the crime scene carried out by the Scientific Police evidencing the spatial orientation.

trajectory from front to back or from right to left. According to the planimetric survey carried out by the Scientific Police Division, the shots followed a north-south and west-east direction (Photograph 8). These findings rule out the official version because the access door to the house was oriented to the east and the shots received by the deceased followed a west-east direction (from right to left). These findings are fully consistent with the witnesses' versions.

4.4.4. Conclusion of the court

In February 2021 the Special Prosecutor's Office for Crimes against Humanity charged three military officers as co-perpetrators of the murders of Silvia Reyes, Laura Raggio and Diana Maidanik.⁶

5. Discussion and conclusions

Since 2013 the historical autopsy method has been used by the Uruguayan judicial system as a means of evidence. In the four cases presented above, the conclusions arrived at after the exhaustive medico-legal analysis of historical documents and witness statements were a significant input for both the prosecutors' accusations and the court decisions.

This evidence based on expert opinion was introduced within the framework of the due process guarantees, where the defense had the opportunity to challenge and/or confront the conclusions of the historical autopsy with their own technical advisors, as well as to freely examine the experts at a hearing.

In addition to contributing to court decisions, the psychosocial benefit of clarifying the facts surrounding human rights violations is well known from the perspective of humanitarian forensic action [17].

Every forensic report must be prudent and free of bias and subjectivity. In the case of historical autopsies, this is of particular importance. Indeed, investigators should not lose sight of the fact that their conclusions must consider that it is an indirect method of observation (based on events witnessed or documented by third parties). Of course, this does not eliminate its ability to serve as evidence, especially when the crime results from the official documents themselves or from the testimonies of the accused [5]. The case of Iván Morales, in which only documents produced by the military dictatorship were available, is the best example of the above.

On the other hand, the aberrant nature of the investigated events when dealing with crimes against humanity, tests the ability of forensic

experts to separate the facts from the emotions that may be triggered by the suffering of direct victims or their families, giving priority to objectivity, work ethics and professionalism required by the task of advising the justice system [18,19].

Funding

The authors declare that they have not received any sources of funding.

CRedit authorship contribution statement

Hugo Rodríguez Almada: Conceptualization, Writing – original draft, Writing – review & editing. **Frances Borches Duhalde:** Conceptualization, Writing – original draft, Writing – review & editing.

Declaration of Competing Interest

Authors have no conflict of interests.

References

- [1] P. Saukko, B. Knight, *The forensic autopsy*, in: P. Saukko, B. Knight (Eds.), *Knigh's Forensic Pathology*, 4th ed., CRC, Florida, 2016, pp. 1–54.
- [2] E.R. Robins, G.E. Murphy, R.H. Wilkinson, S. Gassner, J. Kayes, Some clinical considerations in the prevention of suicide based on a study 134 successful suicides, *Am. J. Public Health* 49 (1959) 888–899.
- [3] B. Madeaa, P. Saukko, A. Olivac, M. Musshof, Molecular pathology in forensic medicine—introduction, *Forensic Sci. Int.* 203 (2010) 3–14, <https://doi.org/10.1016/j.forsciint.2010.07.017>.
- [4] M. Thali, K. Yen, W. Schweitzer, P. Vock, C. Boesch, Ch Ozdoba, G. Schroth, M. Ith Sonnenschein, T. Doernhoefer, E. Scheurer, T. Plattner, R. Dirnhofer, *Virtopsy, a new imaging horizon in forensic pathology: virtual autopsy by postmortem multislice computed tomography (MSCT) and magnetic resonance imaging (MRI)—a feasibility study*, *J. Forensic Sci.* 48 (2) (2003) 386–403.
- [5] H. Rodríguez Almada, F. Verdú Pascual, *La autopsia histórica: presentación del método y su aplicación al estudio de un hecho violento ocurrido en Uruguay en el año 1972*, *Rev. Méd. Urug.* 19 (2003) 126–139.
- [6] G. Riveiro, R. Roó, *Análisis médico-legal del primer caso de responsabilidad médica en Uruguay*, *Rev. Méd. Urug.* 23 (3) (2007) 179–186.
- [7] H. Rodríguez Almada, F. Borches Duhalde, N. Bazán, S. Gamero, F. Lozano, R. Roó, *Métodos de tortura del terrorismo de Estado en Uruguay y valoración médico-legal de su idoneidad para causar lesiones graves o gravísimas*, *Rev. Méd. Urug.* 35 (1) (2019) 42–53, <https://doi.org/10.29193/RMU.35.5.6>.
- [8] H. Rodríguez Almada, *Legal medicine and forensic science in Uruguay*, in: D. H. Ubelaker (Ed.), *The Global Practice of Forensic Science*, Wiley, Oxford, 2015, pp. 335–349.
- [9] M.S. Pollanen, *The pathology of torture*, *Forensic Sci. Int.* 284 (2018) 85–96, <https://doi.org/10.1016/j.forsciint.2017.12.022>.
- [10] P. Saukko, B. Knight, *Abuse of human rights: deaths in custody*, in: P. Saukko, B. Knight (Eds.), *Knigh's Forensic Pathology*, 4th ed., CRC, Florida, 2016, pp. 299–310.

⁶ Court File IUE 91-841/1986: "Reyes Gatan, Arturo Ricardo; Odizzio de Raggio Marta y Potasnik, Flora. Denuncia".

- [11] United Nations, Humans Rights, Office of the High Commissioner, Convention Against Torture and Other Cruel, Inhuman Or Degrading Treatment or Punishment. Ginebra, 1984. Disponible en: (www.ohchr.org/SP/ProfessionalInterest/Pages/CAT.aspx). [Consulta: 14 set. 2018].
- [12] United Nations, Human Rights, Office of the High Commissioner, Manual on the Effective Investigation and Documentation of Torture and Other Cruel, Inhuman or Degrading Treatment or Punishment (Istanbul Protocol), Ginebra: UN, 2004.
- [13] A. Rico, Investigación histórica sobre dictadura y terrorismo de estado en Uruguay (1973–1985), Three volumes, Udelar, Montevideo, 2008.
- [14] A. Rico, J.C. Barrán, G. Caetano, Investigación Histórica sobre Detenidos Desaparecidos, Five volumes, Montevideo, Udelar, 2007.
- [15] Equipo de Investigación Histórica, Investigación histórica de los hechos y la verdad sobre las desapariciones forzadas, asesinatos políticos y fallecidos en el contexto fáctico de las violaciones a los Derechos Humanos ocurridas entre 1968 (junio) y 1985 (marzo). Accesible en: (<https://www.gub.uy/secretaria-derechos-humanos-pasado-reciente/investigacion-historica>).
- [16] Comisión para la Paz, Informe Final, Uruguay, 2003. (www.archivo.presidencia.gub.uy/noticias/archivo/2003/abril/Informe_final.doc).
- [17] U. Hofmeister, S. Navarro, A psychosocial approach in humanitarian forensic action The Latin American perspective, Forensic Sci. Int. 280 (2017) 35–43, <https://doi.org/10.1016/j.forsciint.2017.08.027>.
- [18] Ibero-American Network of Institutions of Legal Medicine and Forensic Sciences, Ethical principles guidelines of the Ibero-American Network of Institutions of Legal Medicine and Forensic Sciences, Rev. Méd. Urug. 34 (2018) 111–114, <https://doi.org/10.29193/rmu.34.2.6>.
- [19] H. Rodríguez Almada, N. Passalacqua, D. Congram, M. Pilloud, As forensic scientists and as people, we must not confuse objectivity with neutrality, J. Forensic Sci. 00 (2021) 1–2, <https://doi.org/10.1111/1556-4029.14785>.