















## SPECIAL REPORT

# International League Against Epilepsy classification and definition of epilepsy syndromes with onset at a variable age: position statement by the ILAE Task Force on Nosology and Definitions

Kate Riney<sup>1,2</sup>  | Alicia Bogacz<sup>3</sup> | Ernest Somerville<sup>4,5</sup>  | Edouard Hirsch<sup>6,7,8</sup>  | Rima Nabhout<sup>9,10,11</sup>  | Ingrid E. Scheffer<sup>12</sup>  | Sameer M. Zuberi<sup>11,13,14</sup> | Taoufik Alsaadi<sup>15</sup>  | Satish Jain<sup>16</sup> | Jacqueline French<sup>17</sup>  | Nicola Specchio<sup>18</sup>  | Eugen Trinka<sup>19,20,21</sup>  | Samuel Wiebe<sup>22</sup>  | Stéphane Auvin<sup>23,24,25</sup>  | Leonor Cabral-Lim<sup>26</sup> | Ansuya Naidoo<sup>27,28</sup> | Emilio Perucca<sup>29,30</sup>  | Solomon L. Moshé<sup>31,32</sup>  | Elaine C. Wirrell<sup>33</sup>  | Paolo Tinuper<sup>34,35</sup>

<sup>1</sup>Neurosciences Unit, Queensland Children's Hospital, South Brisbane, Queensland, Australia

<sup>2</sup>Faculty of Medicine, University of Queensland, South Brisbane, Queensland, Australia

<sup>3</sup>Institute of Neurology, University of the Republic, Montevideo, Uruguay

<sup>4</sup>Prince of Wales Hospital, Sydney, New South Wales, Australia

<sup>5</sup>University of New South Wales, Sydney, New South Wales, Australia

<sup>6</sup>Francis Rohmer Epilepsy Unit, Hautepierre Hospital, Strasbourg, France

<sup>7</sup>National Institute of Health and Medical Research 1258, Strasbourg, France

<sup>8</sup>Federation of Translational Medicine of Strasbourg, University of Strasbourg, Strasbourg, France

<sup>9</sup>Reference Centre for Rare Epilepsies, Assistance Publique – Hôpitaux de Paris, Department of Pediatric Neurology, Necker-Enfants Malades Hospital, Member of Epicare, Paris, France

<sup>10</sup>Imagine Institute, National Institute of Health and Medical Research Mixed Unit of Research 1163, Paris, France

<sup>11</sup>University City University, Paris, France

<sup>12</sup>Austin Health, Royal Children's Hospital, Florey Institute and Murdoch Children's Research Institute, University of Melbourne, Melbourne, Victoria, Australia

<sup>13</sup>Paediatric Neurosciences Research Group, Royal Hospital for Children, Glasgow, UK

<sup>14</sup>Institute of Health & Wellbeing, University of Glasgow, Glasgow, UK

<sup>15</sup>Department of Neurology, American Center for Psychiatry and Neurology, Abu Dhabi, United Arab Emirates

<sup>16</sup>Indian Epilepsy Center, New Delhi, India

<sup>17</sup>New York University Grossman School of Medicine and NYU Langone Health, New York, New York, USA

<sup>18</sup>Rare and Complex Epilepsy Unit, Department of Neuroscience, Bambino Gesù Children's Hospital, Scientific Institute for Research and Health Care, member of EpiCARE, Rome, Italy

<sup>19</sup>Department of Neurology, Christian Doppler University Hospital, Paracelsus Medical University, Center for Cognitive Neuroscience, member of EpiCARE, Salzburg, Austria

<sup>20</sup>Neuroscience Institute, Christian Doppler University Hospital, Center for Cognitive Neuroscience, Salzburg, Austria

<sup>21</sup>Department of Public Health, Health Services Research and Health Technology Assessment, University for Health Sciences, Medical Informatics, and Technology, Hall in Tirol, Austria

Elaine C. Wirrell and Paolo Tinuper are co-senior authors.

This is an open access article under the terms of the Creative Commons Attribution License, which permits use, distribution and reproduction in any medium, provided the original work is properly cited.

© 2022 The Authors. *Epilepsia* published by Wiley Periodicals LLC on behalf of International League Against Epilepsy

<sup>22</sup>Department of Clinical Neurosciences, University of Calgary, Calgary, Alberta, Canada

<sup>23</sup>Institut Universitaire de France, Paris, France

<sup>24</sup>Paediatric Neurology, Assistance Publique – Hôpitaux de Paris, Robert-Debré Hospital, Paris, France

<sup>25</sup>University of Paris, Paris, France

<sup>26</sup>Department of Neurosciences, College of Medicine and Philippine General Hospital, Health Sciences Center, University of the Philippines Manila, Manila, the Philippines

<sup>27</sup>Neurology Unit, Greys Hospital, Pietermaritzburg, South Africa

<sup>28</sup>Department of Neurology, University of KwaZulu Natal, KwaZulu Natal, South Africa

<sup>29</sup>Department of Medicine, Austin Health, University of Melbourne, Heidelberg, Victoria, Australia

<sup>30</sup>Department of Neuroscience, Monash University, Melbourne, Victoria, Australia

<sup>31</sup>Isabelle Rapin Division of Child Neurology, Saul R. Korey Department of Neurology and Departments of Neuroscience and Pediatrics, Albert Einstein College of Medicine, New York, New York, USA

<sup>32</sup>Montefiore Medical Center, Bronx, New York, USA

<sup>33</sup>Divisions of Child and Adolescent Neurology and Epilepsy, Department of Neurology, Mayo Clinic, Rochester, Minnesota, USA

<sup>34</sup>Department of Biomedical and Neuromotor Sciences, University of Bologna, Bologna, Italy

<sup>35</sup>Reference Centre for Rare and Complex Epilepsies, IRCCS Istituto delle Scienze Neurologiche, Bologna, Italy

### Correspondence

Kate Riney, Neurosciences Unit,  
Queensland Children's Hospital, South  
Brisbane, Qld, 4101, Australia.  
Email: kate.riney@health.qld.gov.au

### Abstract

The goal of this paper is to provide updated diagnostic criteria for the epilepsy syndromes that have a variable age of onset, based on expert consensus of the International League Against Epilepsy Nosology and Definitions Taskforce (2017–2021). We use language consistent with current accepted epilepsy and seizure classifications and incorporate knowledge from advances in genetics, electroencephalography, and imaging. Our aim in delineating the epilepsy syndromes that present at a variable age is to aid diagnosis and to guide investigations for etiology and treatments for these patients.

### KEYWORDS

epilepsy with reading-induced seizures, focal epilepsy syndromes, mesial temporal lobe epilepsy with hippocampal sclerosis, progressive myoclonus epilepsies, Rasmussen syndrome

## 1 | INTRODUCTION

Epilepsy can begin at any age across the lifespan. Although many epilepsy syndromes typically begin in the neonate, infant, or child, and there has been greater emphasis on syndrome identification at these ages, there are several important syndromes that begin at a variable age where patient outcomes can be improved by their prompt recognition. The purpose of this paper is to define these epilepsy syndromes. The methodology employed by the International League Against Epilepsy (ILAE) Nosology and Definitions Taskforce (2017–2021) in defining what an epilepsy syndrome is, and their grouping by age at onset, is described in detail by Wirrell et al.<sup>1</sup> An epilepsy syndrome is defined as a characteristic cluster of clinical and electroencephalographic (EEG) features, often supported by specific etiological findings (structural, genetic, metabolic, immune, and infectious). The diagnosis of a syndrome in an individual with epilepsy frequently

### Key Points

- The International League Against Epilepsy presents a classification and definitions for epilepsy syndromes that begin at a variable age
- Syndromes that begin at a variable age can begin both in those aged  $\leq 18$  years and in those aged  $\geq 19$  years
- Syndromes can be broadly divided into generalized, focal, and combined generalized and focal epilepsy syndromes
- Some syndromes can be associated with developmental and/or epileptic encephalopathy in children or with progressive neurological deterioration if they begin later in life
- Examples of etiology-specific epilepsy syndromes are discussed

carries prognostic and treatment implications. Syndromes often have age-dependent presentations and a range of specific comorbidities. A syndrome has a "variable age" of onset if it can begin both in those aged  $\leq 18$  years and in those aged  $\geq 19$  years (i.e., in both pediatric and adult patients). Epilepsy syndromes that typically only begin in the neonate, infant, or child are covered elsewhere.<sup>2,3</sup>

The epilepsy syndromes presenting at a variable age (Figure 1) are broadly divided into the following groups:

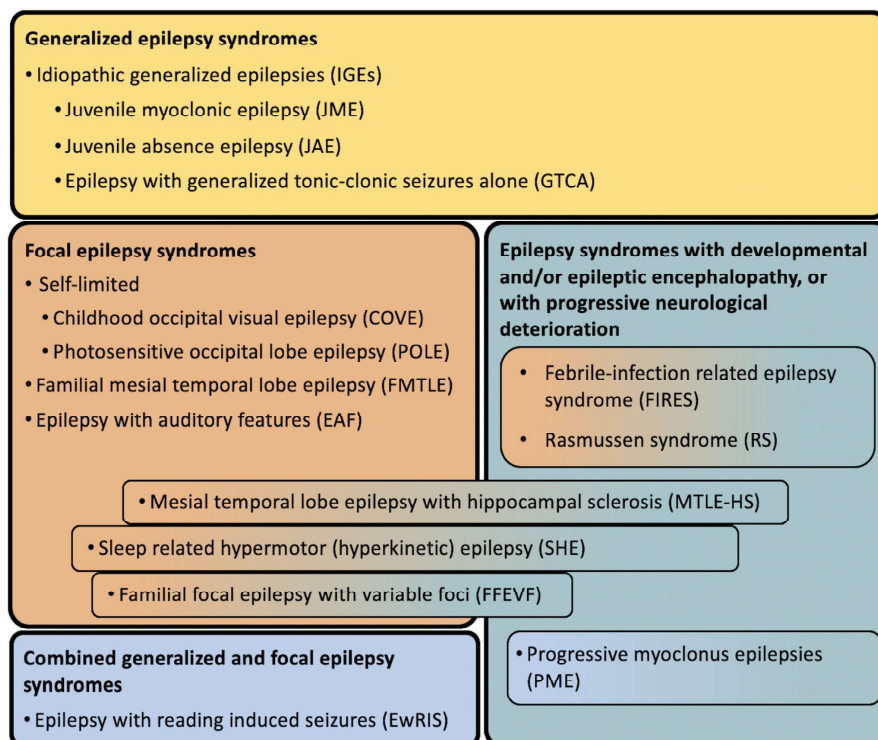
- Generalized epilepsy syndromes, with polygenic etiologies: three of the idiopathic generalized epilepsies (IGEs—juvenile absence epilepsy [JAE], juvenile myoclonic epilepsy [JME], and epilepsy with generalized tonic-clonic seizures alone [GTCA]).<sup>4</sup>
- Self-limited focal epilepsy syndromes with presumed complex inheritance: childhood occipital visual epilepsy (COVE) and photosensitive occipital lobe epilepsy (POLE).
- Focal epilepsy syndromes with genetic, structural, or genetic-structural etiologies: sleep-related hypermotor (hyperkinetic) epilepsy (SHE), familial mesial temporal lobe epilepsy (FMTLE), familial focal epilepsy with variable foci (FFEVF), and epilepsy with auditory features (EAF).

- A combined generalized and focal epilepsy syndrome with polygenic etiology: epilepsy with reading-induced seizures (EwRIS).
- Epilepsy syndromes with developmental encephalopathy (DE), epileptic encephalopathy (EE), or both, and epilepsy syndromes with progressive neurological deterioration:<sup>1</sup> progressive myoclonus epilepsies (PME) and febrile infection-related epilepsy syndrome (FIRES)

In this paper, we also provide definitions for two etiology-specific epilepsy syndromes<sup>1</sup> that have seizure onset at a variable age, while acknowledging that more etiology-specific epilepsy syndromes may be defined in the future:

- Mesial temporal lobe epilepsy with hippocampal sclerosis (MTLE-HS).
- Rasmussen syndrome (RS).

Although the above grouping of syndromes is employed in this paper, it is worth noting that this can be applied flexibly. For example, some patients with SHE (e.g., those with *KCNT1* pathogenic gene variants) can be considered to have a DE, where their neurocognitive impairments are caused by the epilepsy etiology. Patients with



**FIGURE 1** The epilepsy syndromes that begin at a variable age grouped by epilepsy type and whether they are associated with developmental and/or epileptic encephalopathy (D and/or EE) or progressive neurological deterioration. Some patients with the focal epilepsy syndromes MTLE-HS, SHE, and FFEVF may have cognitive, neurologic, or psychiatric impairment related to their etiology or epilepsy (D and/or EE). All patients with established PME (a combined generalized and focal epilepsy syndrome) and FIRES and RS (focal epilepsy syndromes) will have D and/or EE or progressive neurological impairment. The authors note that other epilepsy syndromes may be identified in the future

RS or MTLE-HS can have an EE, as demonstrated by improvement of neurocognitive impairments by successful epilepsy surgery. Patients with PME may initially present with a generalized epilepsy syndrome, indistinguishable from JME, before developing progressive neurological deterioration, when this syndrome can be diagnosed. Therefore, how epilepsy syndromes presenting at a variable age are categorized depends on the clinical presentation and evolution in specific patients.

The nomenclature for each syndrome has been chosen to reflect the key features of the electroclinical phenotype (such as mandatory seizure type) and/or the etiology where this is important for syndrome diagnosis. Thus, the syndrome name reflects the characteristic seizures in JAE, JME, GTCA, SHE, FMTLE, EAF, MTLE-HS, EwRIS, and PME. The terms FFEVF and FMTLE reflect the familial nature of these focal epilepsy syndromes. Although there has been a move away from the use of syndromes named after individuals, the term RS has been retained. The Task Force was unable to propose an alternative for this well-established name that encompasses the epilepsy, distinct imaging features, and progressive neurological deterioration seen in this condition.<sup>1</sup> Whereas Rasmussen encephalitis had been the prevalent term in historic published literature, the Task Force preferred the prospective use of the term RS. Where the term "pathogenic" has been used referring to gene variants causing specific syndromes, we acknowledge that "likely pathogenic"<sup>5</sup> variants in the same gene could also cause the syndrome. In addition to providing definitions for each syndrome, the Task Force also provides criteria for defining the "syndrome without laboratory confirmation" (Tables 3–10).<sup>1</sup> This describes the minimum criteria for syndrome diagnosis, to be used only in resource-limited regions where there is little or no access to EEG, imaging, or genetic studies. For some syndromes, diagnosis is still possible with modified (e.g., computed tomography [CT] instead of magnetic resonance imaging [MRI], video of seizures) or no investigation. For some syndromes, the Task Force acknowledges that diagnosis is not possible in this setting.

## 2 | DEFINITIONS OF EPILEPSY SYNDROMES THAT BEGIN AT A VARIABLE AGE

### 2.1 | Generalized epilepsy syndromes with polygenic etiology

#### 2.1.1 | Idiopathic generalized epilepsies

The most frequent epilepsies that begin in adolescence and adulthood are IGEs, namely JAE, JME, and GTCA.

The IGEs are a subgroup of genetic generalized epilepsies (GGEs) that have particular epidemiological importance, as it is estimated that 15%–20% of all persons with epilepsy have an IGE.<sup>6</sup> For this reason, the IGE syndromes, including those presenting at a variable age (JAE, JME, and GTCA) are presented in a separate paper by Hirsch et al.<sup>4</sup>

### 2.2 | Self-limited focal epilepsy syndromes with presumed complex inheritance

Self-limited focal epilepsies (SeLFEs) account for up to 25% of all pediatric epilepsies.<sup>3</sup> They have age-dependent onset and remission, characteristic seizure semiologies, specific EEG features (with normal EEG background), are drug-responsive, and cognition is typically normal. The etiology is genetic, supported by a higher incidence of epilepsy in families and familial predisposition to the EEG trait. However, no genes have been identified, and the etiology is presumed complex inheritance at a susceptible age. Rare cases show overlap with the IGEs. SeLFEs predominantly begin in childhood, but two syndromes can begin at a variable age: COVE and POLE. Although remission is expected in these syndromes, it may not occur in all patients. COVE is characterized by frequent brief focal aware sensory seizures with visual phenomena during wakefulness, often followed by headache. Onset up to age 19 years has been described.<sup>7</sup> The EEG shows a normal background with interictal occipital sharp- or spike-and-wave, seen mainly in sleep. Remission occurs in 50%–80% of patients within 2–7 years after onset with or without administration of antiseizure medication (ASM).<sup>8,9</sup> POLE is characterized by photic-induced focal aware sensory seizures with visual phenomena. Onset in adulthood has been described.<sup>10</sup> There is a strong female predominance. The EEG shows normal background, with interictal occipital spike- or polyspike-and-wave, facilitated by eye closure and intermittent photic stimulation. Generalized spike-and-wave can also be seen. Both COVE and POLE are discussed in greater detail in a separate paper on epilepsy syndromes that begin in childhood.<sup>3</sup>

### 2.3 | Focal epilepsy syndromes with genetic, structural, or genetic–structural etiologies

The group of focal epilepsy syndromes presenting at a variable age includes a number of syndromes that have been adapted from previous ILAE Commission reports.<sup>11</sup> These syndromes are SHE, FMTLE, FFEVF, and EAF. "Autosomal dominant nocturnal frontal lobe

**TABLE 1** Distinguishing features of SHE, FMTLE, FFEVF, and EAF

Syndrome	Onset (usual)	Clinical	Interictal EEG	Imaging
SHE	Second decade of life	From sleep, brief hyperkinetic or asymmetric tonic/dystonic motor seizures	Background interictal EEG is usually normal; focal (usually frontal) epileptiform abnormality can be seen	Normal, FCD, or acquired structural abnormality
FMTLE	Adolescence or adulthood	Typically, focal aware seizures with intense déjà vu and associated features, e.g., dreamy perceptions, fear or panic, slow motion, visual or auditory illusions, and autonomic manifestations	Background interictal EEG is usually normal or may show mild temporal slowing; temporal epileptiform abnormality can occasionally be seen	Normal, rarely hippocampal atrophy or increased T2 signal
FFEVF	First or second decade of life	Focal seizures, semiology dependent on focal cortical area involved in an individual, but constant in that individual	Background interictal EEG is usually normal; focal epileptiform abnormality can be seen	Normal or FCD
EAF	Second or third decade of life	Sensory seizures (auditory), cognitive seizures with receptive aphasia	Background interictal EEG is usually normal; focal (usually temporal) epileptiform abnormality can be seen	Usually normal, although posterior temporal FCD reported

Abbreviations: EAF, epilepsy with auditory features; EEG, electroencephalogram; FCD, focal cortical dysplasia; FFEVF, familial focal epilepsy with variable foci; FMTLE, familial mesial temporal lobe epilepsy; SHE, sleep-related hypermotor (hyperkinetic) epilepsy.

epilepsy" has been renamed SHE to reflect current understanding that this syndrome includes characteristic motor seizure types (hyperkinetic seizures and/or motor seizures with tonic/dystonic features), predominantly from sleep, and that these can be of extrafrontal onset. A wider range of etiologies is now associated with these syndromes, derived from advances in imaging, genetic, and EEG investigations. Thus, where relevant, these syndromes have been expanded to encompass both structural and genetic etiologies that may result in the same electroclinical presentation. The Task Force considered whether other disorders that result in seizures with characteristic clinical and EEG features implicating specific focal brain networks should be considered epilepsy syndromes. The Task Force decided to include definitions only for the focal epilepsy syndromes presented in this paper but acknowledges that some other focal epilepsies (e.g., insular, anterior cingulate, occipital) may meet the agreed definition of an epilepsy syndrome.

Helpful for diagnosis of most of these focal epilepsy syndromes is their distinct seizure semiology (Table 1). The typical seizure semiology of the hyperkinetic seizures occurring during sleep in SHE or the focal sensory auditory seizures in EAF suggest the syndrome diagnosis and help target investigations to specific brain regions and genetic etiologies. The diagnosis of some of these syndromes requires careful review of family history. Pathogenic variants in several genes have been identified as causing these syndromes (Table 2), which may be inherited, arise de novo, or be due to somatic pathogenic gene variants. Family history may be missed due to reduced penetrance, variable severity and semiology of seizures, and misdiagnosis in affected family members.<sup>12,13</sup> If family members have focal aware seizures (e.g., auditory symptoms, déjà vu, or brief nocturnal motor events alone), these may not have been identified as seizures, unless family members are asked by a clinician who is aware of their significance. In some families, only detailed study of all affected individuals with clinical, EEG, and imaging phenotyping (e.g., excluding family members with acquired structural brain abnormality), together with genetic investigation, will allow a confident diagnosis of the specific familial focal epilepsy syndrome.<sup>14</sup> Diagnosis can be further complicated by the same pathogenic gene variants causing different focal epilepsy syndromes (e.g., pathogenic variants in *DEPDC5* have been identified in SHE, FMTLE, and FFEVF). The epilepsy syndrome diagnosed in a family may therefore depend on whether all family members can be confirmed to have the same phenotype (e.g., SHE, FMTLE, EAF) or whether there is different focal seizure semiology seen in affected individuals in the family (FFEVF).

Focal epilepsy syndrome	Related genes
SHE	<i>CHRNA4, CHRNA2, CHRNB2, DEPDC5, KCNT1, NPRL2, NPRL3, PRIMA1</i>
FMTLE	<i>DEPDC5</i> (Mendelian inheritance is rare, FMTLE typically displays complex inheritance)
FFEVF	<i>TSC1, TSC2, DEPDC5, NPRL2, NPRL3</i>
EAF	<i>LG11, RELN, MICAL1</i>

Abbreviations: EAF, epilepsy with auditory features; FFEVF, familial focal epilepsy with variable foci; FMTLE, familial mesial temporal lobe epilepsy; SHE, sleep-related hypermotor (hyperkinetic) epilepsy.

**TABLE 2** Genetic focal epilepsy syndromes and genes currently implicated

**TABLE 3** Core diagnostic criteria for sleep-related hypermotor (hyperkinetic) epilepsy

	Mandatory	Alert <sup>a</sup>	Exclusionary
Seizures	Brief focal motor seizures with hyperkinetic or asymmetric tonic/dystonic features occurring predominantly from sleep	Seizures predominantly from the awake state	Seizures only during wakefulness Generalized onset seizures
EEG		Frequent epileptiform abnormality outside of the frontal regions Generalized epileptiform abnormality	
Age at onset		<10 or >20 years	<2 months or >64 years
Development at onset		Moderate to severe intellectual disability	
Neurological exam		Focal neurological examination abnormalities	
An MRI is not required for diagnosis but should be done to evaluate for underlying etiology. An ictal EEG is not required for diagnosis.			
Syndrome without laboratory confirmation: In resource-limited regions, SHE can be diagnosed if other mandatory and exclusionary criteria are met, and the patient has witnessed or video-recorded hyperkinetic seizures during sleep.			

Abbreviations: EEG, electroencephalogram; MRI, magnetic resonance imaging; SHE, sleep-related hypermotor (hyperkinetic) epilepsy.

<sup>a</sup>Alert criteria are absent in the vast majority of cases, but rarely can be seen. Their presence should result in caution in diagnosing the syndrome and consideration of other conditions.

### 2.3.1 | Sleep-related hypermotor (hyperkinetic) epilepsy

SHE (Table 3) is characterized by clusters of motor seizures occurring from sleep. Seizures are abrupt in onset and offset, and typically brief (<2 min), with preserved awareness and a stereotyped hyperkinetic or asymmetric dystonic/tonic motor pattern. This epilepsy syndrome, particularly if associated with a structural brain abnormality or specific gene (e.g., *KCNT1*), can be drug-resistant. SHE encompasses and replaces the previous epilepsy syndromes of hypnogenic–nocturnal paroxysmal dystonia–epilepsy, nocturnal frontal lobe epilepsy (NFLE), and autosomal dominant NFLE, and includes genetic and structural etiologies.<sup>15–20</sup> Although the name "sleep-related hypermotor epilepsy" is the term used in recent literature for this syndrome,<sup>15,20–24</sup> the Task Force notes that "hyperkinetic" rather than "hypermotor" is the currently

accepted term for the focal motor seizure with vigorous movement that can be seen in this syndrome.<sup>25</sup> The Task Force agreed that the name for this syndrome could be either "sleep-related hyperkinetic epilepsy" or "sleep-related hypermotor epilepsy," as some patients may have hyperkinetic seizures alone, but others may have focal motor seizures with tonic/dystonic features.

#### Epidemiology

SHE is a rare syndrome, with an estimated prevalence of the nonfamilial form in the adult population of 1.8–1.9 per 100 000.<sup>21,22</sup>

#### Clinical context

Age at seizure onset is mostly in the first 2 decades of life, typically in adolescence (11–14 years), but has ranged from 2 months to 64 years.<sup>13,21,26,27</sup> There is a slight male sex predominance.<sup>21</sup> Neurological examination is normal.

Perinatal history, developmental milestones, and cognition are typically normal. Intellectual disability and neuropsychiatric or behavior disorders have been reported in SHE.<sup>23,28,29</sup>

### Course of illness

The course of SHE is predominantly related to the underlying etiology.<sup>21</sup> Most patients have normal intellect and normal imaging, and respond to first-line ASMs.<sup>30</sup> Patients with intellectual disability, neurological or imaging abnormality, or seizures in wakefulness are less likely to achieve sustained seizure remission.<sup>21,30</sup> Epilepsy surgery, in selected etiologies, may be effective. The best surgical outcome is seen when the etiology is a well-defined structural pathology, especially focal cortical dysplasia (FCD) type IIb.<sup>31</sup>

### Seizures

Focal motor seizures with vigorous hyperkinetic or asymmetric tonic/dystonic features are seen, usually with autonomic signs (tachycardia, tachypnea, irregular respiratory rhythm), vocalization, and negative emotional expression such as fear.<sup>24</sup> There may be head and eye deviation. Hyperkinetic movements involve proximal limb or axial muscles, producing irregular large amplitude movements, such as pedaling, pelvic thrusting, jumping, thrashing, or rocking movements.<sup>25</sup> Focal motor seizures may be subtle clinically (previously termed "paroxysmal arousals") or may have longer duration and greater complexity (such as "epileptic wandering").<sup>13</sup> Patients may describe a focal aware sensory or cognitive seizure before the motor features commence. Focal to bilateral tonic-clonic seizures can occur.<sup>13,21,30</sup> Although occurrence of seizures from sleep is characteristic of this syndrome, seizures from the awake state occur in 27%–45% of patients at some time in their life.<sup>13,21,26</sup>

### Electroencephalogram

The EEG background is typically normal. The awake EEG is nonepileptiform in most (50%–90%) patients.<sup>13</sup> During sleep, interictal epileptiform abnormalities are seen over the frontal areas in approximately 50% of patients (Figure 2A).<sup>13</sup> Ictal EEG may not show definitive ictal patterns, be obscured by movement artifact, or show evolving sharp or spike-and-wave discharges, rhythmic slow activity, or diffuse background flattening over frontal areas (Figure 2B). Postictal focal slowing may be seen. Prolonged video-EEG recording is the best diagnostic test to identify events with stereotyped semiology from sleep to confirm the diagnosis, especially in cases without a clear surface ictal EEG correlate. Intracranial EEG recordings (e.g., stereo-EEG) have demonstrated that ictal discharges may start in various extrafrontal areas (insulo-opercular, temporal, and parietal cortices).<sup>24,32–34</sup>

### Imaging

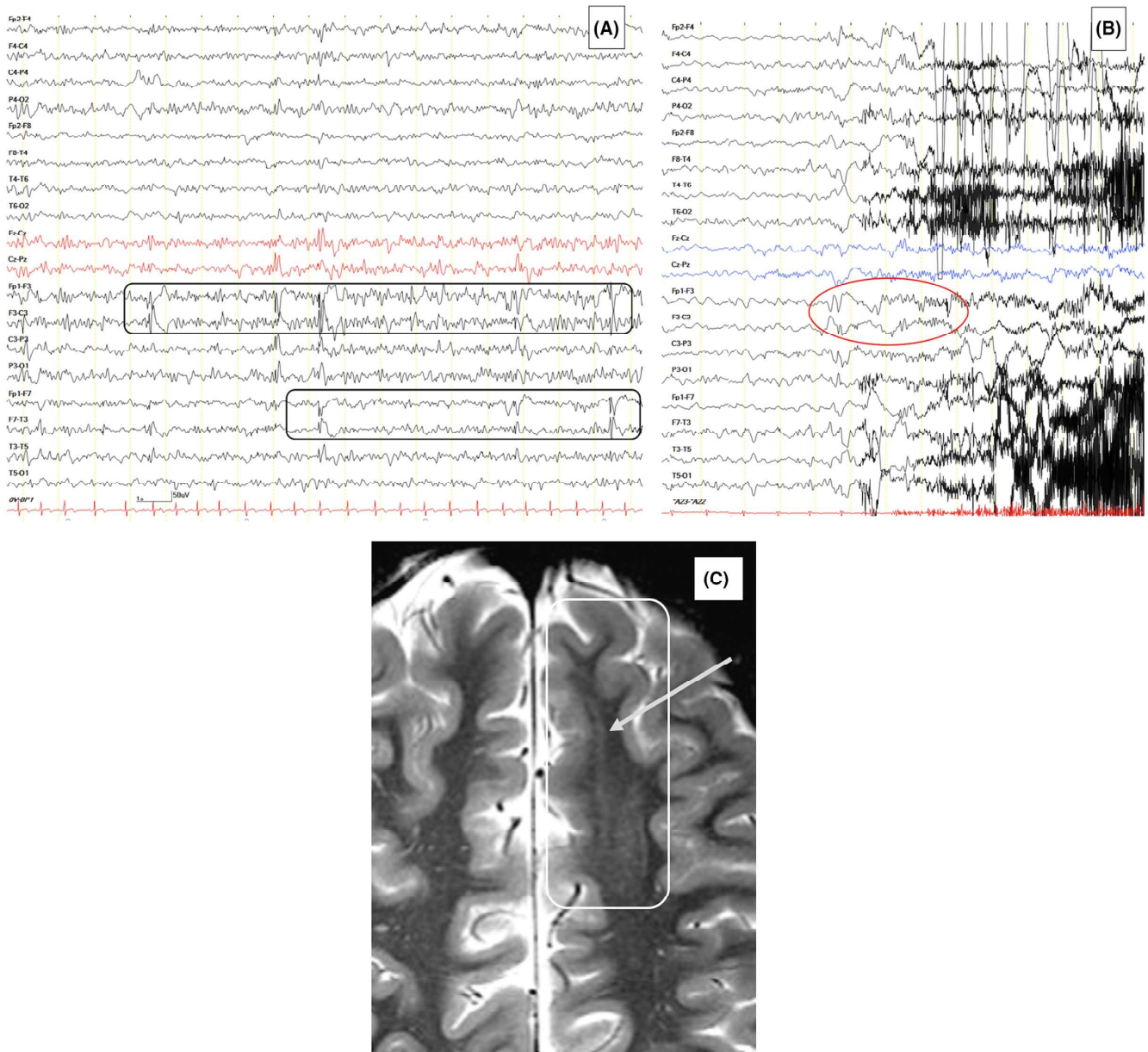
Neuroimaging is usually normal. Occasionally, a structural brain abnormality is found, most commonly FCD (Figure 2C) but also, less commonly, an acquired structural pathology.<sup>20</sup>

### Genetics

The etiology of SHE may be genetic, genetic-structural, or acquired. Family history should be carefully sought, but is not expected in sporadic or acquired SHE.<sup>30</sup> Familial SHE is usually inherited in an autosomal dominant fashion (autosomal dominant SHE [ADSHE]), with a penetrance of approximately 70%.<sup>26</sup> A pathogenic gene variant is found in approximately 19% of ADSHE and in 7% of sporadic SHE.<sup>15</sup> Genetic causes of ADSHE include pathogenic variants in GATOR1 complex genes (*DEPDC5*, less frequently *NPRL2* or *NPRL3*),<sup>16–19</sup> in acetylcholine receptor subunit genes (*CHRNA4*, less frequently *CHRN2* or *CHRNA2*),<sup>35–37</sup> and in the sodium-activated potassium channel gene *KCNT1*.<sup>28</sup> Individuals with GATOR complex pathogenic gene variants may have FCD, with implications for epilepsy surgery.<sup>15</sup> Individuals with *KCNT1* pathogenic variants have a more severe form of SHE, with intellectual disability, psychosis, and sometimes regression,<sup>28,29</sup> and higher penetrance in families. Rare families with autosomal recessive SHE are described, and pathogenic variants in *PRIMA1* have been identified in one family.<sup>38</sup>

### Differential diagnoses

- Non-rapid eye movement (REM) parasomnias: Patients with SHE may be misdiagnosed as having parasomnias, often for some time before the epilepsy is recognized.<sup>39</sup> Seizures in SHE are typically brief (<2 min), with abrupt onset/offset, have stereotyped motor features from seizure to seizure, and can occur nightly with clustering through the night (from sleep onset to the early morning), and there is often preserved awareness during the seizure. Parasomnias are longer in duration (>10 min), have variable features from event to event, and are less frequent, often singular in a night, and prominent 1–2 h after falling asleep; the patient is confused during the event, with no memory of it afterward.
- Psychogenic nonepileptic seizures (PNES): Patients with SHE may be misdiagnosed as having PNES, because they may have preserved awareness in the presence of bilateral movements during their seizures, and the ictal EEG may not show definitive ictal patterns. SHE may be differentiated from PNES by the stereotyped hyperkinetic features, brevity, and clustering of seizures through the night from sleep, whereas events in PNES are less stereotyped and occur during wakefulness.



**FIGURE 2** Interictal epileptiform activity in an 8-year-old boy with sleep-related hypermotor (hyperkinetic) epilepsy. (A) Electroencephalogram shows repetitive spiking over the anterior regions of the left hemisphere with phase reversals at F3 and F7 electrodes (boxes). (B) A hyperkinetic seizure during non-rapid eye movement sleep in the same boy. The tracing is almost masked by muscle artifact due to movement. It is possible to see a leading sharp wave followed by fast activity (ellipse) in the left frontal region. (C) Magnetic resonance imaging shows a subtle band heterotopia in the subcortical white matter of the left frontal lobe, seen as a linear signal abnormality, isointense to overlying cortex, running in an anterior–posterior direction in the white matter (arrow), which is subtly brighter on this T2 image compared to the same area in the right frontal lobe (box)

- REM behavior disorder: This is a REM parasomnia that begins usually later in life (>50 years). Hyperkinetic movements are not stereotyped and correspond to vivid dreaming.
- FFEVF: Whereas seizures compatible with SHE can occur in an individual in a family with FFEVF, familial SHE is distinguished from FFEVF by all affected individuals in the family having seizures compatible with SHE.<sup>14</sup>
- Other focal seizures occurring predominantly from sleep: These do not have the characteristic hyperkinetic or asymmetric tonic/dystonic features seen in SHE.

### 2.3.2 | Familial mesial temporal lobe epilepsy

FMTLE (Table 4) is a common focal epilepsy syndrome with a complex mode of inheritance, typically with onset in adolescence or adulthood.<sup>40</sup> The syndrome is generally associated with focal aware seizures with semiology referable to the mesial temporal lobe, especially prominent déjà vu. Patients have a normal MRI, and seizures respond to treatment. Some families have also been described that have a clinically heterogeneous form of FMTLE,

**TABLE 4** Core diagnostic criteria for familial mesial temporal lobe epilepsy

	<b>Mandatory</b>	<b>Alert<sup>a</sup></b>	<b>Exclusionary</b>
Seizures	Focal cognitive (particularly déjà vu), sensory, or autonomic seizures		Generalized onset seizures
EEG		Generalized epileptiform abnormality	
Development at onset		Intellectual disability	
Neurological exam		Focal abnormalities on neurological examination	
Imaging	Normal or hippocampal atrophy/sclerosis		
Other studies: genetics, etc.	Family history of individuals with focal seizures that arise from the mesial temporal lobe		
An MRI is required for diagnosis to exclude other causes. An ictal EEG is not required for diagnosis.			
Syndrome without laboratory confirmation: In resource-limited regions, MRI is required to exclude other structural etiologies.			

Abbreviations: EEG, electroencephalogram; MRI, magnetic resonance imaging.

<sup>a</sup>Alert criteria are absent in the vast majority of cases, but rarely can be seen. Their presence should result in caution in diagnosing the syndrome and consideration of other conditions.

**TABLE 5** Core diagnostic criteria for familial focal epilepsy with variable foci

	<b>Mandatory</b>	<b>Alert<sup>a</sup></b>	<b>Exclusionary</b>
Seizures	Focal onset seizures		Generalized onset seizures
EEG		Generalized epileptiform abnormality	
Age at onset		Neonatal onset	
Development at onset			Moderate to profound intellectual disability
Neurological exam		Focal neurological examination abnormalities	
Imaging	Normal or focal cortical dysplasia		
Other studies: genetics, etc.	Family history of individuals with focal seizures that arise from cortical regions that differ between family members		Family history of focal seizures that occur exclusively before 20 months of age
An MRI is required for diagnosis. Family history of focal seizures might be incidental, due to an acquired cause. An ictal EEG is not required for diagnosis.			
Syndrome without laboratory confirmation: In resource-limited regions, FFEVF can be diagnosed without EEG in a patient if other mandatory and exclusionary criteria are met. However, an MRI or CT is required to exclude other structural etiologies.			

Abbreviations: CT, computed tomography; EEG, electroencephalogram; FFEVF, familial focal epilepsy with variable foci; MRI, magnetic resonance imaging.

<sup>a</sup>Alert criteria are absent in the vast majority of cases, but rarely can be seen. Their presence should result in caution in diagnosing the syndrome and consideration of other conditions.

comprising antecedent febrile seizures, MRI evidence of hippocampal atrophy, and a less favorable response to ASMs.<sup>41,42</sup>

### Epidemiology

It has been estimated that FMTLE accounts for almost one fifth of newly diagnosed cases of nonlesional mesial temporal lobe epilepsy.<sup>43</sup> Because of its mild and subtle

features, FMTLE is often unrecognized without directed questioning of relatives.

### Clinical context

Age at seizure onset varies between 3 and 63 years, with symptoms usually starting in adolescence or adulthood.<sup>40,44</sup> A female predominance has been reported.<sup>40,44,45</sup> Individuals with FMTLE generally have

**TABLE 6** Core diagnostic criteria for epilepsy with auditory features

	<b>Mandatory</b>	<b>Alert<sup>a</sup></b>	<b>Exclusionary</b>
Seizures	Focal sensory auditory seizures and/or focal cognitive seizures with receptive aphasia		Generalized onset seizures Other focal onset seizures
EEG		Generalized epileptiform abnormality	
Development at onset			Moderate or severe intellectual disability
Neurological exam		Focal neurological examination abnormalities	
Imaging	Normal or focal cortical dysplasia		
An MRI is required for diagnosis to exclude other causes. An ictal EEG is not required for diagnosis.			
Syndrome without laboratory confirmation: In resource-limited regions, MRI is required to exclude other structural etiology.			

Abbreviations: EEG, electroencephalogram; MRI, magnetic resonance imaging.

<sup>a</sup>Alert criteria are absent in the vast majority of cases, but rarely can be seen. Their presence should result in caution in diagnosing the syndrome and consideration of other conditions.

**TABLE 7** Core diagnostic criteria for mesial temporal lobe epilepsy with hippocampal sclerosis

	<b>Mandatory</b>	<b>Alert<sup>a</sup></b>	<b>Exclusionary</b>
Seizures	Focal aware or impaired awareness seizures with initial semiology referable to medial temporal lobe networks (see text)	Initial semiology referable to networks other than mesial temporal (e.g., throat discomfort, clonic or dystonic movements, somatic sensory symptoms, hyperkinetic activity, visual symptoms, auditory symptoms, laughter)	Generalized onset seizures
EEG		Consistent lack of temporal epileptiform abnormality, despite repeated EEGs Generalized epileptiform abnormality High-amplitude, centrottemporal spikes with horizontal dipole Interictal epileptiform abnormality or focal slowing outside of the temporal regions or over the posterior temporal region	Recorded seizures with generalized onset EEG seizures recorded with onset in regions outside the temporal lobe
Age at onset		<2 years	
Development at onset		Moderate to severe intellectual disability	
Neurological exam		Focal neurological findings such as hemiparesis (excluding facial asymmetry)	
Imaging	Hippocampal sclerosis (unilateral or bilateral) on MRI		
An MRI documenting hippocampal sclerosis is required for diagnosis. An ictal EEG is not required for diagnosis.			
Syndrome without laboratory confirmation: In resource-limited regions, an MRI is required for confirmation of diagnosis.			

Abbreviations: EEG, electroencephalogram; MRI, magnetic resonance imaging.

<sup>a</sup>Alert criteria are absent in the vast majority of cases, but rarely can be seen. Their presence should result in caution in diagnosing the syndrome and consideration of other conditions.

normal intellectual development and no associated neurological abnormalities. A history of febrile seizures is uncommon in patients with the typical presentation but may be present in patients with the more severe, and often drug-resistant, phenotype.

### *Course of illness*

In cohorts diagnosed in first seizure clinics and with a proactive investigation of family members, FMTLE typically displays a favorable prognosis.<sup>40</sup> Many affected individuals consider their déjà vu experiences as physiological

phenomena, and thus do not seek medical attention. In such cases, seizures have little or no impact on daily routines. Diagnosis is often triggered by appearance of a focal to bilateral tonic-clonic seizure, inquiry into previous unrecognized seizures, and ascertainment of potentially affected relatives.<sup>43</sup> Individuals with mild manifestations may not require drug treatment. When treatment is indicated, most patients achieve seizure freedom on their initially prescribed ASM, few require polytherapy, and only exceptionally is epilepsy surgery required.<sup>40</sup> In cohorts identified in a specialized assessment setting because of drug resistance or presurgical evaluation, the course of epilepsy is less favorable, with more frequent seizures and need for epilepsy surgery.<sup>41,46</sup> Seizure outcomes in individuals requiring epilepsy surgery do not appear to differ from patients with sporadic MTLE.<sup>47</sup>

### Seizures

Patients typically present with focal aware seizures mainly consisting of intense déjà vu, which is reported by >70% of affected individuals. Manifestations commonly associated with déjà vu include dreamy perceptions, fear or panic, slow motion, visual or auditory illusions, and autonomic manifestations (a rising visceral or epigastric sensation, nausea, tachycardia, sweating, flushing, or pallor).<sup>40,44</sup> These seizures may progress to impaired awareness, or rarely to bilateral tonic-clonic seizures. In most patients with the typical form of FMTLE, seizures are mild and occur infrequently.<sup>40</sup>

### Electroencephalogram

In approximately 60% of affected individuals, the EEG is normal or shows mild temporal slowing.<sup>40,43</sup> The remaining cases show interictal temporal epileptiform abnormality, more often unilateral. Focal epileptiform abnormalities may be activated by sleep in some individuals.<sup>44</sup>

### Imaging

Patients with the typical presentation show no overt MRI abnormalities.<sup>40</sup> The presence of hippocampal atrophy or increased T2 signal is generally associated with poorer responsiveness to medical treatment.<sup>41,42</sup>

### Genetics

Evidence for a genetic etiology is provided by the observation of a high concordance in monozygotic twins compared with dizygotic twins.<sup>44</sup> The syndrome occurs in relatives of probands with a lower frequency than that predicted by dominant Mendelian models, and in only a minority of families is the frequency compatible with recessive inheritance.<sup>40</sup> Based on these findings, FMTLE is conceptualized mainly as a genetic syndrome with complex (either polygenic or multifactorial) inheritance. Rare

families displaying Mendelian inheritance with pathogenic variants in *DEPDC5* have been reported.<sup>48</sup>

### Differential diagnoses

- FFEVF: Whereas seizures compatible with MTLE can occur in an individual in a family with FFEVF, for FMTLE to be diagnosed, all affected individuals in the family must have seizures compatible with MTLE.
- MTLE with structural brain abnormality: Patients with FMTLE have a family history of individuals with seizures compatible with MTLE and who do not have structural brain abnormalities on MRI, except for rare cases with hippocampal atrophy/sclerosis.
- Physiological déjà vu: Physiological déjà vu differs from epileptic déjà vu in that it is typically mild, fleeting, rare (yearly or less), does not occur in clusters, is not associated with other features (including progression to other seizure types), and is often precipitated by specific circumstances (e.g., visiting a new place, performing specific actions).<sup>43</sup>

## 2.3.3 | Familial focal epilepsy with variable foci

FFFEVF (Table 5) is an autosomal dominant familial focal epilepsy syndrome, with incomplete penetrance, characterized by focal seizures arising from different cortical regions (most commonly frontal or temporal) in different family members with variable severity, but with every individual in a family having a single focal seizure type. This syndrome was previously known as "familial partial epilepsy with variable foci" and "autosomal dominant partial epilepsy with variable foci."<sup>12,14</sup> Etiologies include genetic and structural causes. Most cases are responsive to ASMs. In appropriately selected patients with drug-resistant seizures and FCD, epilepsy surgery may result in full remission. Surgical assessment and counseling may be informed by identification of specific genetic etiologies, for example, a pathogenic gene that infers risk of multiple dysplasias.

### Epidemiology

There are no epidemiological studies of the prevalence of this epilepsy syndrome. It is considered rare.

### Clinical context

Age at seizure onset is typically in the first to second decade (peak = 12–13.5 years) but has a wide range even in the same family, ranging from 1 month to 52 years.<sup>12,14</sup> There is no reported sex predominance. Antecedent, birth, and neonatal history is typically normal. Neurological examination is normal. Early developmental milestones,

intellect, and cognition are typically normal, although mild intellectual disability and neuropsychiatric features including autism spectrum disorder and behavioral disorders have been reported.<sup>49,50</sup>

#### *Course of illness*

Most cases are responsive to ASMs; however, drug resistance rates may be up to 30%.<sup>51</sup> Epilepsy surgery, in selected cases, may be effective and result in full remission of seizures.<sup>52</sup>

#### *Seizures*

Focal seizures occur, with semiology depending on the focal network involved in the individual. Every affected individual in a family typically has one focal seizure type. Focal cognitive, sensory, autonomic, or motor seizures have been described. Seizures can arise from sleep, wakefulness, or both. Focal to bilateral tonic-clonic seizures may occur.

#### *Electroencephalogram*

The EEG background is normal. The interictal EEG usually shows focal epileptiform abnormalities (frontal, temporal, centroparietal more than occipital).<sup>14</sup> In every affected individual in a family, this focal area remains constant over time. Epileptiform abnormality is enhanced by sleep deprivation and sleep. Ictal EEG demonstrates focal ictal patterns related to the focal brain network involved in the individual.

#### *Imaging*

Neuroimaging may be normal or may show FCD (which may be subtle).<sup>16,52</sup>

#### *Genetics*

The etiology of FFEVF may be genetic or genetic-structural with co-occurring FCD (typically FCD type II).<sup>52</sup> Inheritance is autosomal dominant with incomplete penetrance.<sup>14,53</sup> Pathogenic variants in *DEPDC5*, *NPRL2*, and *NPRL3* have been identified. Some families with pathogenic variants in *TSC1* or *TSC2* meet criteria for this syndrome.

#### *Differential diagnoses*

- Familial SHE: Whereas nocturnal seizures compatible with SHE are common in individuals in families with FFEVF,<sup>14</sup> for this syndrome, all affected individuals in the family must have seizures compatible with SHE. A predominance of awake seizures is also a useful distinction between FFEVF and SHE.<sup>14</sup>
- FMTLE: For this syndrome, all affected individuals in the family must have seizures compatible with MTLE.
- Familial EAF: For this syndrome, all affected individuals in the family must have seizures compatible with EAF.

### 2.3.4 | Epilepsy with auditory features

EAF (Table 6) is a focal epilepsy syndrome that presents in adolescence/adulthood without any antecedent history and is characterized by focal aware seizures with auditory symptoms and/or receptive aphasia. Patients rarely may have focal to bilateral tonic-clonic seizures. Some patients have seizures precipitated by specific sounds. This syndrome was previously known as autosomal dominant lateral temporal lobe epilepsy and autosomal dominant partial epilepsy with auditory features. EAF may occur as a familial focal epilepsy syndrome, familial EAF (FEAF), which may be inherited in an autosomal dominant fashion (autosomal dominant EAF [ADEAF]) with reduced penetrance.

#### *Epidemiology*

The prevalence of this syndrome is unknown.

#### *Clinical context*

Age at seizure onset is typically 10–30 years (range = .5–54 years).<sup>54</sup> There is no reported sex predominance. Antecedent, birth, and neonatal history is typically normal. Neurological examination is normal. Early developmental milestones and intellect/cognition are typically normal.

#### *Course of illness*

Seizure outcomes can range from mild seizures with spontaneous remission to highly drug-resistant seizures. Those with structural lesions may be treated surgically.<sup>54</sup> The cumulative rate of seizure remission in those followed for at least 5 consecutive years was approximately 50% by 30 years from epilepsy diagnosis.<sup>54</sup> Predictors of poor long-term outcome are early age at onset (<10 years), focal epileptiform abnormality on interictal EEG, and focal aware cognitive seizures with complex auditory hallucinations.<sup>54</sup>

#### *Seizures*

Focal aware sensory (auditory) and/or cognitive (receptive aphasia) seizures are mandatory for this syndrome. Auditory sensory symptoms typically consist of simple unformed sounds (e.g., humming, buzzing, or ringing), or less commonly auditory distortions (such as alteration in volume) or complex sounds (e.g., specific songs or voices). Ictal receptive aphasia consists of an inability to understand spoken language in the absence of an impairment of awareness. Additional focal seizure symptoms can occur, including vision alteration (distortions of faces/objects) and vertigo.<sup>55,56</sup> Focal impaired awareness and focal to bilateral tonic-clonic seizures (often from sleep) may occur. The focal aware seizures may not have been appreciated as epileptic until these

seizures occur; therefore, careful history is important to elicit a history of these prior seizure types. Reflex seizures precipitated by sound (e.g., a ringing telephone) occur in some patients.<sup>54</sup>

#### *Electroencephalogram*

The interictal EEG is normal in most patients. If an abnormality is seen, this is characterized by focal (usually temporal) sharp-and-wave or spikes; these may also be widespread.<sup>54</sup> The EEG may be activated by hyperventilation, sleep deprivation, and sleep. Ictal EEG recordings are rarely reported.

#### *Imaging*

Neuroimaging is usually normal, but rarely a structural etiology may be found.<sup>55</sup>

#### *Genetics*

EAF mostly occurs sporadically, although FEAF also occurs, and has autosomal dominant inheritance (ADEAF) with incomplete penetrance.<sup>54</sup> Pathogenic variants (or microdeletions) in *LGII* (epitempin) or *RELN* account for approximately half of ADEAF cases.<sup>57–60</sup> Pathogenic gene variants in *MICAL1* are a rarer cause.<sup>59</sup> Pathogenic variants in *DEPDC5*, *CNTNAP2*, and *SCN1A* have also been reported.<sup>61</sup>

#### *Differential diagnoses*

- FFEVF: Whereas seizures compatible with EAF can occur in an individual in a family with FFEVF, for FEAF to be diagnosed, all affected individuals in the family must have seizures compatible with EAF.
- Psychiatric disorders: Auditory hallucinations are easily distinguished from EAF by the more chronic nature and complexity of psychiatric auditory hallucinations.
- Tinnitus: This disorder is common and thus may be coincidentally present in the patient's family. This is distinguished from focal sensory auditory seizures by the usually longer duration of tinnitus in disorders of the peripheral auditory system, and the presence of other features of seizures accompanying ictal auditory sensations.

## 2.4 | Etiology-specific epilepsy syndromes

Etiology-specific epilepsy syndromes can be identified when there is an etiology for the epilepsy that is associated with a clearly defined, relatively uniform and distinct clinical phenotype in most affected individuals (clinical presentation, seizure types, comorbidities, course of illness, and/or response to specific therapies), as well

as consistent EEG, neuroimaging and/or genetic correlates.<sup>1</sup> Two etiology-specific epilepsy syndromes that begin at a variable age are discussed in this section. Future work may expand on the definitions of more etiology-specific epilepsy syndromes. This may aid earlier clinical recognition of some autoimmune or metabolic (e.g., glucose transporter 1 deficiency) etiologies that benefit from prompt targeted treatment.

### 2.4.1 | Mesial temporal lobe epilepsy with hippocampal sclerosis

MTLE is a frequent focal epilepsy in adults, although it also presents in childhood. Although many contributing factors can lead to HS, including genetic, genetic-structural, and immune pathologies, the syndrome of MTLE-HS (Table 7) requires imaging confirmation of HS—the cause of the epilepsy—for diagnosis. This epilepsy syndrome is often drug-resistant; however, epilepsy surgery may transform outcome to full remission of the epilepsy.

#### *Epidemiology*

There are few population-based epidemiological studies of MTLE. Most studies derive from tertiary care (e.g., epilepsy surgery) centers with referral bias toward drug-resistant patients. The prevalence of TLE was calculated at 1.7/1000 people in one population study.<sup>62</sup> The estimated prevalence of drug-resistant MTLE-HS is much lower, at .51–.66 per 1000 persons, with an estimated incidence of 3.1–3.4 per 100 000 people per year.<sup>63</sup>

#### *Clinical context*

Age at seizure onset is typically in adolescent and young adult years, although later or earlier onset is reported. There is no sex predominance. Antecedent, birth, and neonatal history is typically normal. Neurological examination is normal, although reduced facial movement may be noted on the contralateral side.<sup>64</sup> A past history of febrile seizures in early childhood may be found,<sup>65–67</sup> and prolonged febrile seizures in childhood may cause HS.<sup>65,68</sup> Early developmental milestones are within normal limits. Cognitive comorbidity is recognized, with deficits in verbal memory associated with MTLE-HS affecting the dominant (usually left) mesial temporal lobe and deficits in visual memory associated with MTLE-HS affecting the nondominant temporal lobe.

#### *Course of illness*

MTLE-HS is often drug-resistant. Epilepsy surgery, in selected etiologies, may transform outcome from uncontrolled drug-resistant seizures to full remission of epilepsy.

The best surgical outcome is seen when the structural abnormality is well defined on imaging.

### Seizures

Focal aware or impaired awareness seizures occur with semiological features referable to medial temporal lobe networks. Focal aware seizures may be autonomic (e.g., a rising epigastric sensation, abdominal discomfort, nausea, retching, pallor, flushing, tachycardia), cognitive (e.g., déjà vu, jamais vu), emotional (e.g., fear), or sensory (e.g., olfactory, gustatory) seizures. Focal aware seizures may be the only initial seizure type, may not be recognized as seizures, and may occur for some time before a diagnosis of epilepsy is considered. In focal impaired awareness seizures, there is usually behavioral arrest and often automatisms that may be oral (chewing, lip-smacking, swallowing), vocal (speech, in nondominant MTLE-HS), or gestural. Upper limb automatisms may be unilateral and may lateralize the seizure to the ipsilateral hemisphere. Contralateral upper limb dystonia may develop. Contralateral head and eye version can occur,<sup>69,70</sup> although in some patients, there may be an initial ipsilateral head turn before the contralateral version.<sup>71</sup> Speech may be preserved in seizures of nondominant MTLE-HS. Conversely, aphasia is common with dominant MTLE-HS. Seizures have a gradual offset, and typically last 1–5 min, although focal aware seizures can be briefer. After focal impaired awareness seizures, patients may experience confusion lasting several minutes. Seizures may progress to a focal to bilateral tonic-clonic seizure, and there may be contralateral (face greater than arm and leg) clonic jerking and head turning before the focal to bilateral tonic-clonic phase.

Focal autonomic, cognitive, emotional, and sensory seizures can also arise in other brain networks; however, the onset symptoms and signs during seizure progression and the postictal period are different. The following initial symptoms and signs suggest seizure onset in brain networks other than those in the mesial temporal region: throat discomfort, clonic or dystonic movements, somatic sensory symptoms, hyperkinetic activity, visual symptoms, auditory symptoms, and laughter.

### Electroencephalogram

The EEG background is normal or may show focal slowing over the temporal region(s). Focal slowing can be enhanced by hyperventilation. Anterior or midtemporal epileptiform abnormality is characteristic and is often increased during sleep (Figure 3A). Temporal intermittent rhythmic delta activity may also be present.<sup>72</sup> Epileptiform abnormality may occasionally be activated by hyperventilation.<sup>73</sup> It may be bilateral and independent, or bilaterally synchronous. Ictal EEG (Figure 3B) commonly

commences with focal electrodecrement and low-voltage fast activity replacing the normal EEG background. This evolves to rhythmic frontotemporal alpha or theta, with or without superimposed spikes or sharp-and-wave. The first clinical symptoms or signs may precede the emergence of surface ictal rhythm on EEG. Postictal ipsilateral slowing is common.

### Imaging

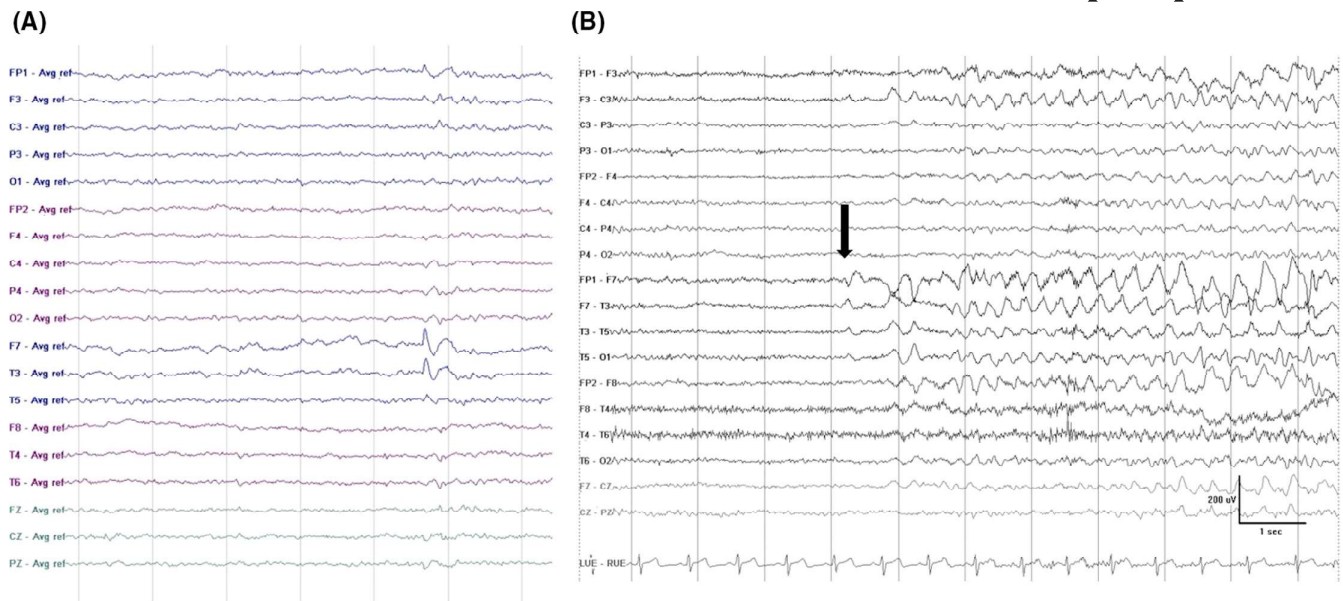
HS is characterized by decreased hippocampal volume (best seen on coronal magnetization-prepared rapid acquisition gradient echo or T1-weighted sequences at right angles to the long axis of the hippocampus), with increased hippocampal signal intensity (best seen on coronal fluid-attenuated inversion recovery [FLAIR] and T2 sequences; Figure 4). Up to 15% of patients may have HS coexisting with another structural abnormality, such as FCD or acquired pathologies ("dual pathology")<sup>74–76</sup>; these lesions should therefore be carefully sought. The occurrence of FCD with HS in ILAE classifications of FCD is categorized as FCD type IIIa<sup>76</sup>; this may be associated with earlier age at seizure onset in childhood and warrants extra care in presurgical evaluation to determine the primary lesion driving the epilepsy.

### Genetics

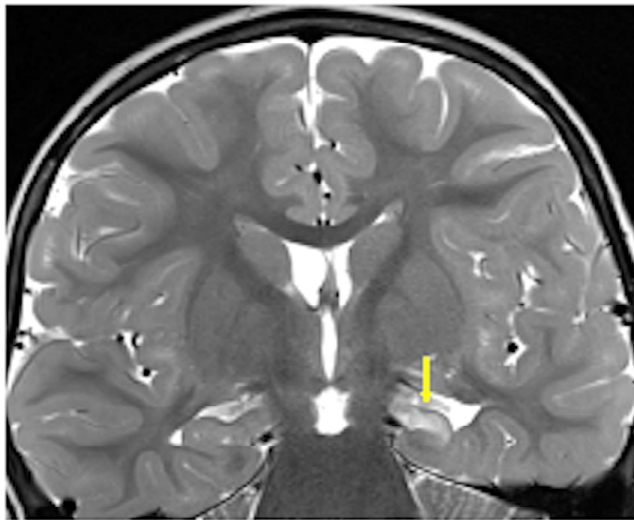
MTLE-HS is predominantly an acquired pathology<sup>65</sup>; therefore, genetic studies are not often indicated. Prolonged seizures, including febrile seizures, can cause HS; therefore, genetic epilepsies that are accompanied by febrile seizures, especially if prolonged (e.g., Dravet syndrome or genetic epilepsy with febrile seizures plus; genes *SCN1A* or *SCN1B*), can predispose an individual to the development of MTLE-HS. Finding one of these genes may drive changes in treatment (e.g., considering the possibility of seizure aggravation by sodium channel-blocking ASMs), which may improve seizure control. Identification of a genetic etiology is not necessarily a contraindication to epilepsy surgery in drug-resistant patients, but may inform counseling.<sup>77</sup>

### Differential diagnoses

- Viral (e.g., herpesviruses) and autoimmune limbic encephalitis can present with seizures with temporal semiology, but subsequently patients develop acute or subacute encephalopathy.
- MTLE due to causes other than HS: Examples include FCD and genetic causes (see FMTLE).
- Extratemporal seizures that propagate to medial temporal lobe networks, especially from the orbitofrontal cortex and insular-opercular region, but also from the occipital or parietal lobes.
- Nonepileptic seizures may be difficult to differentiate from MTLE when seizures do not progress to impaired awareness, or motor features, as the surface EEG may



**FIGURE 3** Electroencephalogram in a 53-year-old patient with mesial temporal lobe epilepsy with hippocampal sclerosis (left-sided hippocampal sclerosis). (A) Interictal: There is continuous polymorphic slowing and a spike followed by a slow wave at the F7 electrode (drowsy, average reference montage). (B) Ictal: Seizure onset is depicted by the arrow (longitudinal bipolar montage)



**FIGURE 4** T2-weighted imaging in a coronal plane at right angles to the long axis of the hippocampus showing increased signal and loss of volume in the left hippocampus (arrow)

be normal during focal aware seizures, and incidental abnormalities of the hippocampus (such as asymmetry in size) are not uncommon. Adding to the challenge is that anxiety and mood disorders are common comorbidities in patients with MTLE.

#### 2.4.2 | Rasmussen syndrome

RS (previously known as Rasmussen encephalitis; Table 8) is a disorder that presents in children, adolescents, and

young adults. Progressive hemispheric atrophy is seen on neuroimaging. The cause of this is unknown, and no causative antibody has been identified. Cerebrospinal fluid can show normal findings, but may show a mild pleocytosis, mildly elevated protein, and oligoclonal bands. Patients have focal seizures (usually motor seizures, including *epilepsia partialis continua*), which progress over time in frequency and severity. A progressive contralateral hemiparesis develops. The diagnosis is based on the characteristic clinical presentation and imaging findings.<sup>78,79</sup> Brain biopsy may not be required, but if performed shows multifocal cortical inflammation, neuronal loss, and gliosis confined to one hemisphere. RS is considered an etiology-specific epilepsy syndrome, because although the cause of the hemispheric atrophy is unknown, this pathology itself is the etiology of the electroclinical syndrome of RS.

#### *Epidemiology*

RS is a rare disease, with an incidence of 1.7–2.4 per 10 million individuals.<sup>80,81</sup>

#### *Clinical context*

The age at onset is 1–10 years (median = 6 years). Late onset forms, starting in adolescent or adult life, comprise approximately 10% of cases.<sup>82</sup> Both sexes are equally affected. Antecedent and birth history is usually normal; however, pregnancy or perinatal complications have been reported in 19% of patients in one surgical series operated on between 1945 and 1987.<sup>83</sup> At initial presentation, children are typically developmentally normal. Over time, cognitive impairment emerges. At onset, neurological

**TABLE 8** Core diagnostic criteria for Rasmussen syndrome

	<b>Mandatory</b>	<b>Alert<sup>a</sup></b>	<b>Exclusionary</b>
Seizures	Focal/hemispheric seizures that often increase in frequency over weeks to months	Focal onset independently in both hemispheres (only 2% of RS is bilateral)	Generalized onset seizures
EEG	Hemispheric slowing and epileptiform abnormality	Generalized spike-and-wave	
Age at onset		Adolescence or adulthood	
Development at onset		Abnormal development prior to seizure onset	
Neurological exam			Hemiparesis present at onset (if permanent hemiparesis is present immediately following status epilepticus, consider HHE)
Imaging	Progressive hemiatrophy (early insula and head of caudate atrophy; see text)	Lack of hyperintense signal and/or atrophy of the ipsilateral caudate head, and/or lack of T2/FLAIR hyperintense signal of gray or white matter	Imaging shows Sturge–Weber syndrome
Other studies: genetics, etc.			Metabolic cause of epilepsy partialis continua Condition is due to specific antibody-mediated encephalitis
Long-term outcome	Drug-resistant epilepsy Progressive neurological deficits		
An MRI is required for diagnosis. An ictal EEG is not required for diagnosis.			
Syndrome in evolution: Children with drug-resistant, focal hemispheric seizures that progressively increase in frequency, with progressive neurological deficits, but whose MRI remains normal, and where other metabolic and autoimmune etiologies have been excluded, should be highly suspected of having emerging RS.			
Syndrome without laboratory confirmation: In resource-limited regions, RS can be diagnosed without EEG in a patient with focal/hemispheric onset seizures, who shows the typical clinical evolution, who meets all other mandatory and no exclusionary clinical criteria, and has no alerts. However, imaging (CT or MRI) is required to exclude other causes.			

Abbreviations: CT, computed tomography; EEG, electroencephalogram; FLAIR, fluid-attenuated inversion recovery; HHE, hemiconvulsion–hemiplegia–epilepsy syndrome; MRI, magnetic resonance imaging; RS, Rasmussen syndrome.

<sup>a</sup>Alert criteria are absent in the vast majority of cases, but rarely can be seen. Their presence should result in caution in diagnosing the syndrome and consideration of other conditions.

examination is usually normal. Rarely, children may present with unilateral limb dystonia or choreoathetosis prior to seizure onset. Over time, patients develop a progressive hemiparesis, and may develop hemianopia. Acquired language dysfunction is seen in cases that affect the dominant hemisphere. Progression of RS is slower in patients with adolescent or adult onset than in those with childhood onset, and final deficits may be less severe.<sup>82,84</sup>

#### *Course of illness*

RS is associated with frequent drug-resistant seizures and progressive neurological deterioration (hemiparesis, homonymous hemianopia, cognitive impairment). There are typically three stages of RS: an initial prodromal phase

(lasting months to years, although shorter in younger children), with infrequent seizures and mild hemiparesis; an acute phase (lasting months to years, although shorter in younger children), with increasingly frequent seizures, at times with epilepsy partialis continua, and progressive hemiparesis, hemianopia, cognitive, and language (the latter if dominant hemisphere) deterioration; and finally, a chronic phase, with permanent stable hemiparesis and other neurological disabilities, and continued seizures (although less frequent than in the acute stage).<sup>79</sup> Hemispheric disconnection surgery (so-called hemispherotomy) or hemispherectomy are the only known definitive treatments for seizures that can alter the course of the condition.

### Seizures

Focal seizures, usually motor seizures, occur and may be clinically subtle at onset. In childhood onset RS, seizures are typically focal aware seizures, whereas in older onset patients, focal impaired awareness seizures are more commonly seen.<sup>84</sup> The clinical motor manifestations are contralateral to the affected hemisphere. Seizures typically increase in frequency over weeks to months and can include epilepsy partialis continua, with ongoing twitching of one side of the body, most commonly the face and upper extremity. Focal seizures may evolve to bilateral tonic-clonic seizures. Focal atonic seizures may also occur. Seizures may rapidly engage bilateral brain networks, and seizures that appear generalized may be seen.

### Electroencephalogram

The background EEG may be normal at initial presentation, but usually shows slowing, with loss of normal rhythms and sleep architecture on the affected side. With time, background asymmetry becomes more prominent. Epileptiform abnormality is typically seen maximally over the affected hemisphere (Figure 5). With time, it may be seen in the contralateral hemisphere; this does not exclude a patient from surgical evaluation. Epileptiform abnormality can be facilitated by sleep. The ictal EEG shows focal ictal discharges. Seizures may arise from several foci within the affected hemisphere. Epilepsia partialis continua is often not accompanied by a clear ictal rhythm on scalp EEG. With atrophy of the affected hemisphere, ictal EEG may show asymmetric emphasis of the seizure on the contralateral side. However, true independent focal seizure onset in both hemispheres ("bilateral" RS) has also rarely been reported (2% of cases).<sup>79</sup>

### Imaging

MRI is usually normal in the early phase of the disease, although RS occurring in patients with FCD or vascular abnormalities has been reported.<sup>85</sup> T2/FLAIR hyperintensity may be noted in the insular region. Ipsilateral atrophy of the caudate head is also an early sign (Figure 6). With time, there is progressive atrophy of the affected hemisphere (Figure 7), often starting in the insular region, with enlargement of the temporal horn of the lateral ventricle and Sylvian fissure.<sup>79,86</sup> Atrophy is usually seen within the first year of onset and correlates with progressive hemiparesis.

### Genetics

This disorder is not considered genetic in etiology.

### Differential diagnoses

- Autoimmune encephalitis: This is not expected to be limited to one hemisphere, and cognitive, behavioral, and psychiatric symptoms and movement disorder typically predate seizures.

- Mitochondrial disorders: Examples are polymerase gamma (POLG)-related disorders and mitochondrial encephalomyopathy, lactic acidosis, and stroke-like episodes (MELAS).
- Hemispheric structural abnormalities (e.g., vascular, FCD type I): These may be associated with seizures, hemiparesis, and hemiatrophy on MRI; however, progressive decline in motor and cognitive function over time is not expected.
- Hemiconvulsion–hemiplegia–epilepsy syndrome: This condition is characterized by an initial prolonged seizure, which is then followed immediately by nonprogressive hemiparesis.

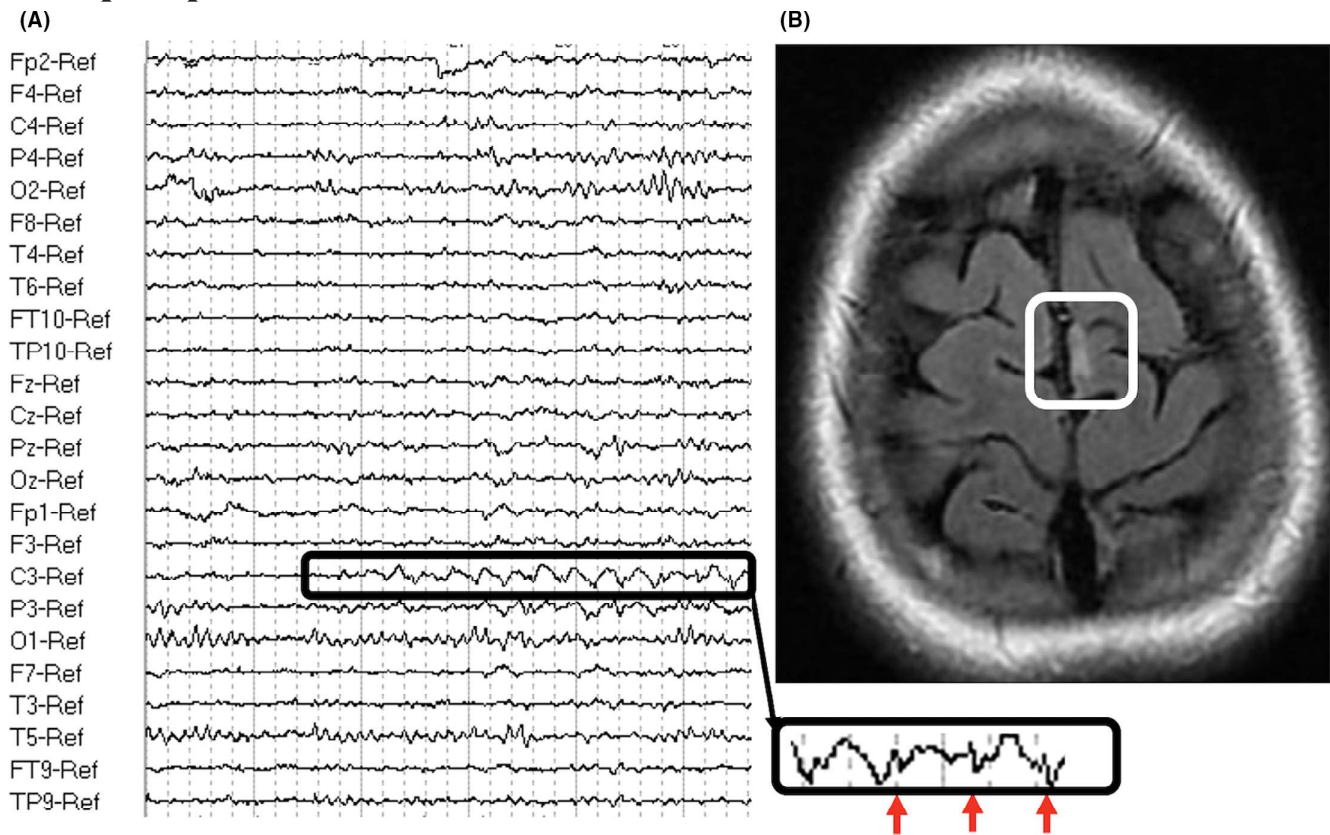
## 2.5 | Combined generalized and focal epilepsy syndrome with polygenic etiology

### 2.5.1 | Epilepsy with reading-induced seizures

EwRIS (Table 9) is a rare combined generalized and focal epilepsy syndrome, characterized by reflex myoclonic seizures affecting orofacial muscles triggered by reading. If reading continues, these may worsen, and a generalized tonic–clonic seizure may occur. Good history-taking is therefore critical for diagnosis, as is awareness of this syndrome, as the task-specific eliciting of symptoms can result in misdiagnosis of seizures as PNES, as tics, or as stuttering. Seizures are elicited mainly by reading, but also by other tasks related to language. Prognosis is favorable, as spontaneous seizures are not expected, and seizures are responsive to treatment and can be avoided through reducing exposure to the triggering stimulus. In most patients, seizures require long-term treatment, although some patients may experience remission in time.

#### WHAT IS A REFLEX SEIZURE?

A reflex seizure is a seizure that is consistently or nearly consistently elicited by a specific stimulus, which may be sensory, sensory–motor, or cognitive. The stimulus may "elementary" (e.g., light, elimination of visual fixation, touch), "complex" (e.g., tooth-brushing, eating), or cognitive (e.g., reading, calculating, thinking, listening to music). Such a stimulus will have a high likelihood of eliciting a seizure, in contrast to a stimulus that may facilitate epileptiform abnormality (such as photoparoxysmal responses on EEG) or evoke a seizure, but not consistently.



**FIGURE 5** A 12-year-old female with Rasmussen syndrome affecting the left hemisphere, 18 months after seizure onset. (A) The interictal electroencephalogram (referential montage) shows a low-voltage spike wave discharge at C3 (box shows the spikes denoted by arrows). (B) The axial fluid-attenuated inversion recovery magnetic resonance imaging performed at the same age shows focal hyperintensity and atrophy in the left supplementary motor area (square)

#### ARE EPILEPSIES WITH REFLEX SEIZURES EPILEPSY SYNDROMES?

The Task Force considered whether conditions other than EwRIS, in which reflex seizures occur, might be epilepsy syndromes. Although patients with these conditions have in common a specific stimulus triggering their seizures, their electroclinical features, etiologies, and prognosis are diverse. Therefore, the Task Force decided not to include these as epilepsy syndromes at the current time. Photosensitivity is a common feature of many epilepsy syndromes, and the Task Force concluded that disorders associated with photosensitivity were too diverse, when grouped, to satisfy criteria for an epilepsy syndrome.

#### Epidemiology

This is a rare epilepsy syndrome; therefore, true incidence is unknown.

#### Clinical context

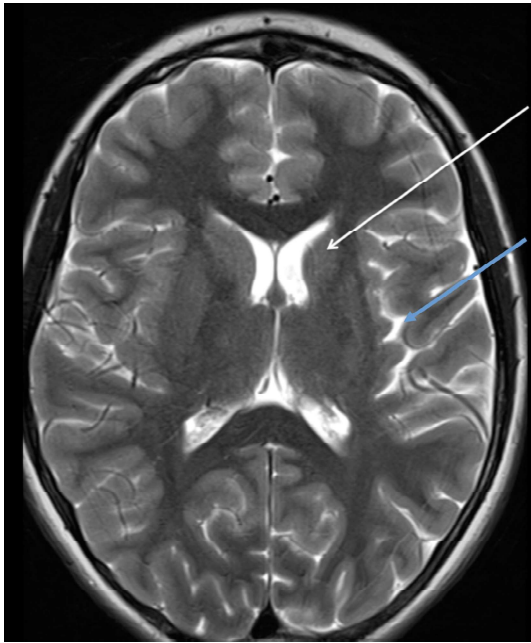
Age at onset is typically in the late teens (median = 17.5 years, range = 10–46 years).<sup>87</sup> A male sex predominance (~2:1) is recognized.<sup>87,88</sup> Antecedent, birth, and neonatal history is typically normal. Development and cognition are typically normal. Neurological examination is normal.

#### Course of illness

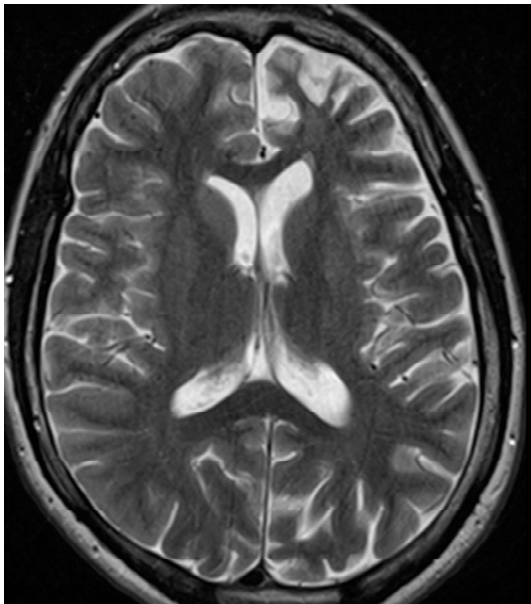
Due to the rarity of this syndrome (case reports only), little is known about its course. Prognosis is generally considered to be favorable, with a good response to ASMs described in the literature, and potential for remission in a minority of patients with age.<sup>88</sup> Reducing exposure to the triggering stimulus may be successful in reducing seizures; however, limiting reading can result in significant restrictions in capacity for education, employment, lifestyle, and even for religious practice.<sup>89</sup>

#### Seizures

Low-amplitude myoclonic jerks occur, mainly affecting the masticatory, oral, and perioral muscles (jaw, lip, tongue). These can cause a clicking sensation, stuttering,



**FIGURE 6** T2-weighted axial image in a patient with Rasmussen syndrome showing atrophy of the caudate (white arrow) with subtle loss of volume of the left insular region (blue arrow, evident as increased sulcal spaces)



**FIGURE 7** T2-weighted axial image in the same patient with Rasmussen syndrome as for Figure 6, showing increased atrophy of the left hemisphere with time (interval of 8 years between imagings)

or altered speech.<sup>90</sup> The reading time to seizure onset varies from patient to patient and in individual patients.<sup>87</sup> If the patient continues to read after the myoclonus appears, the myoclonus can increase in severity, spread to trunk and limb muscles, and have associated impaired awareness, or

a tonic–clonic seizure may emerge. Orofacial myoclonic jerks may be precipitated not only by reading, but also by other language-related tasks (language-induced seizures) in the same patient, for example, by talking (when tense or argumentative), writing, or by making complex decisions.<sup>87,91</sup> Hand myoclonic jerks are seen in those with writing precipitation of seizures. In an individual patient, the trigger may be specific; for example, seizures may occur when reading silently but not when reading aloud,<sup>92</sup> when reading a specific language but not mathematics,<sup>86</sup> when reading music, or when reading one language but not another.<sup>89</sup> A minority of patients with EwRIS have been described to have co-occurring ocular and visual ictal manifestations (e.g., blinking, difficulty with ocular fixation, nystagmus, complex visual hallucinations)<sup>87,91</sup> or rare spontaneous myoclonus.<sup>87</sup>

#### *Electroencephalography*

The EEG background is normal. Interictal epileptiform abnormality may not be seen, although it may be facilitated during sleep or on awakening. Myoclonic seizures are accompanied by brief sharp, spike, sharp-and-wave or spike-and-wave activity (which may be low voltage; see Figure 8). Approximately 75% of cases show generalized ictal discharges, and approximately 25% have bilateral but asymmetric or unilateral discharges (lateralizing to the dominant hemisphere in all; 10% have focal temporoparietal discharges).<sup>87</sup> These may be difficult to distinguish from accompanying myogenic artifact. Seizure features may be difficult to appreciate on video, due to the subtle nature of the orofacial myoclonus and limited resolution of facial features during video-EEG.

#### *Imaging*

Neuroimaging is expected to be normal. If there are atypical features to the clinical presentation, imaging should be considered to exclude a structural etiology.

#### *Genetics*

A positive family history of epilepsy, usually one of the IGE syndromes or a GGE, is found in 20%–40% of patients with EwRIS.<sup>87,91</sup> This is considered to reflect a strong genetic contribution.<sup>88</sup>

#### *Differential diagnoses*

- **Nonepileptic stuttering:** Nonepileptic stuttering is characterized by involuntary repetitions, prolongations of sounds, syllables, words, or phrases as well as involuntary silent pauses during which the person who stutters is unable to produce sounds.
- **JME:** In EwRIS, the myoclonus is all or nearly all (i.e., 80%–90%) reading or language-related,<sup>88,93</sup> is localized to the jaw, and does not predominantly occur in

**TABLE 9** Core diagnostic criteria for epilepsy with reading-induced seizures

	<b>Mandatory</b>	<b>Alert<sup>a</sup></b>	<b>Exclusionary</b>
Seizures	Reflex myoclonic seizures affecting orofacial muscles triggered by reading/language-related tasks	Prominent myoclonic jerks affecting the upper limbs	All other seizure types, except generalized tonic-clonic seizures
EEG			Background slowing on EEG, excluding in the postictal phase of a generalized tonic-clonic seizure
Age at onset		>20 years	
Development at onset	Normal		
Neurological exam	Normal		
Imaging	Normal		
An MRI is required for diagnosis to exclude a structural cause.			
An ictal EEG is not required; however, observation during reading (either directly or by video) is highly recommended, as it shows the characteristic myoclonus affecting orofacial muscles.			
Syndrome without laboratory confirmation: In resource-limited regions, this syndrome can be diagnosed in children and adults who meet all mandatory criteria and have no exclusionary seizure types.			

Abbreviations: EEG, electroencephalogram; MRI, magnetic resonance imaging.

<sup>a</sup>Alert criteria are absent in the vast majority of cases, but rarely can be seen. Their presence should result in caution in diagnosing the syndrome and consideration of other conditions.

the morning.<sup>87</sup> In JME, the myoclonus occurs spontaneously (although cognitive induction by praxis—thinking or decision-making—has been recognized),<sup>94</sup> affects the upper extremities, is more frequently seen in the morning, and a photoparoxysmal response may be seen on EEG.

- Focal seizures in occipitotemporal networks rarely can be induced by reading, but there is no orofacial myoclonus.<sup>95</sup>

## 2.6 | Epilepsy syndromes with developmental and/or epileptic encephalopathy and epilepsy syndromes with progressive neurological deterioration

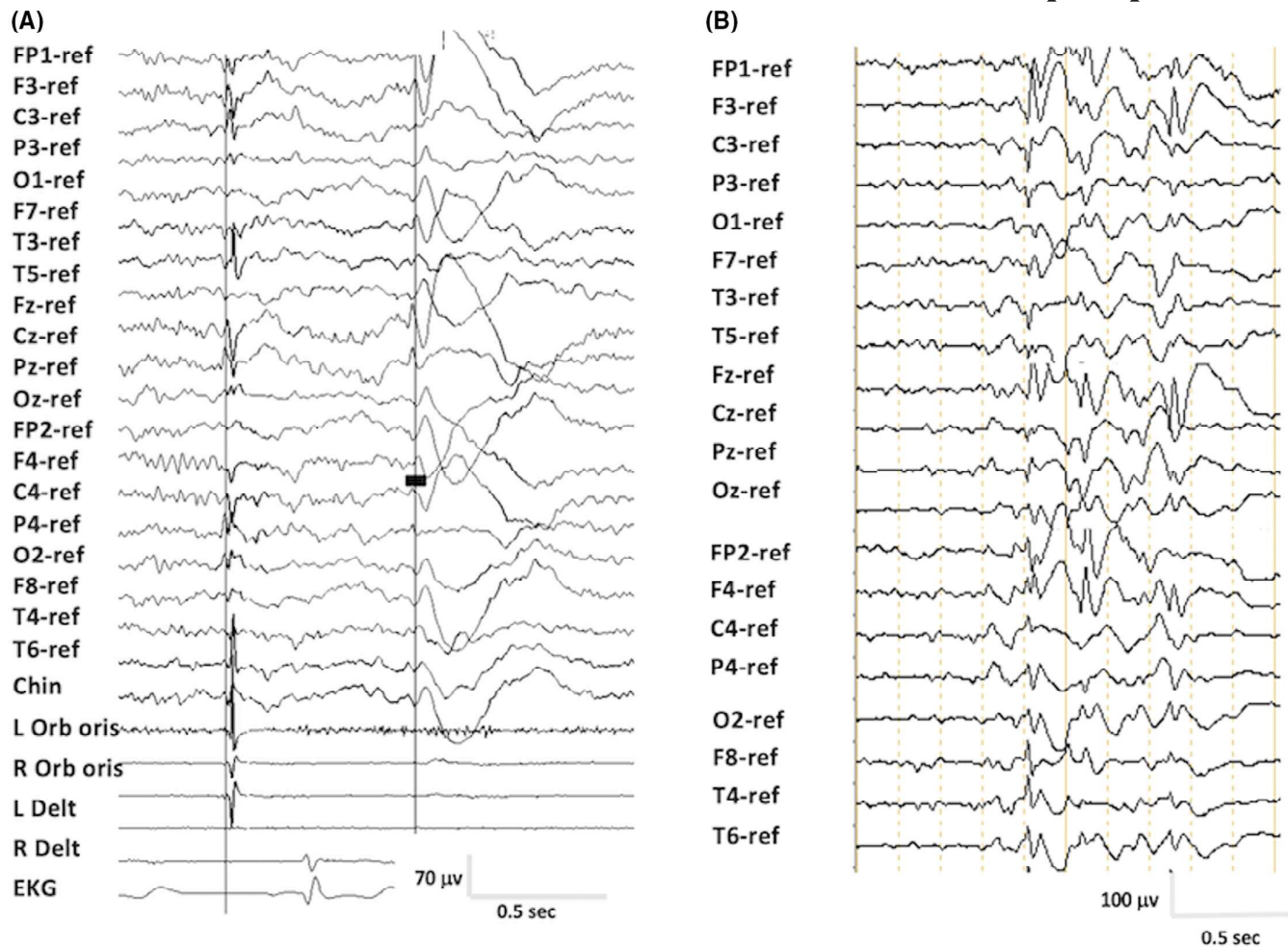
The term "DE" applies when there is onset of a condition manifesting with cognitive, neurological, or psychiatric impairment, stagnation, or regression, due directly to the underlying etiology. In contrast, an EE is present when the encephalopathy is caused by the epileptic activity. The term "developmental and epileptic encephalopathy" (DEE) is used when both factors contribute to the patient's condition. The term "DE" can be challenging to apply in an older individual who has completed all development normally. To address this, the Task Force proposes the term "progressive neurological deterioration" instead of DE for such patients who develop cognitive, neurological, or psychiatric impairment due directly to the underlying etiology. In this section of the paper, we discuss PME, which, depending on the etiology and age at onset, can be

an epilepsy syndrome with DEE or an epilepsy syndrome with progressive neurological deterioration. Depending on age at onset, the etiology-specific epilepsy syndrome RS (discussed earlier) is also an epilepsy syndrome with DEE or with progressive neurological deterioration. FIRES can begin at a variable age but is rare in adults; it is discussed in a separate paper on epilepsy syndromes that begin in childhood.<sup>3</sup>

### 2.6.1 | Progressive myoclonus epilepsies

The syndrome PME (Table 10) is rare, and is caused by a heterogenous group of underlying genetic etiologies. It is recognized in the presence of (1) myoclonus, (2) progressive motor and cognitive impairment, (3) sensory and cerebellar signs, and (4) abnormal background slowing on EEG<sup>96</sup> that (5) appear in an individual with prior normal development and cognition. Photosensitivity is a common feature of many etiologies of PME. There may be a family history, with autosomal recessive inheritance in most cases, but PME can be sporadic. The prevalence varies from one region to another, with higher prevalence in isolated regions or in cultures that favor consanguineous marriages. The geographical and ethnic background of the patient is, therefore, important data for the diagnosis of the underlying genetic cause.

The following entities account for the majority of PME: Unverricht–Lundborg disease (ULD), Lafora disease, neuronal ceroid lipofuscinosis (NCL), mitochondrial disorders (myoclonic epilepsy with ragged-red



**FIGURE 8** A 42-year-old woman with epilepsy with reading-induced seizures from 18 years of age. Electroencephalogram shows (A) spikes with perioral bilateral myoclonia, followed by a bilateral spike-and-wave; and (B) 3–6-Hz generalized spike-and-wave discharges without a seizure (consistent asymmetry of the spike-and-wave discharges was not seen throughout the EEG recording)

fibers, POLG-related disorders, MELAS), and sialidosis. Three of these are discussed further in this paper and summarized in Table 11. Less commonly, the following entities may be identified: dentatorubral–pallidoluysian atrophy, juvenile Huntington disease, action myoclonus–renal failure syndrome, juvenile neuroaxonal dystrophy, pantothenate–kinase-associated neurodegeneration, neuroserpin inclusion body disease, leukoencephalopathy with vanishing white matter, early onset Alzheimer disease, *GOSR2* pathogenic variants, myoclonic epilepsy in Down syndrome, GM2 gangliosidosis, tetrahydrobiopterin deficiency, noninfantile neuronopathic Gaucher disease, Niemann–Pick disease type C, and celiac disease. Genetic testing is required for most of these conditions to confirm the clinical diagnosis and identify the etiology. Histological or biochemical testing can be used to support the diagnosis in specific circumstances (e.g., Lafora bodies in sweat duct cells, ragged red fibers in biopsied muscle).

#### *Unverricht–Lundborg disease*

*Also known as epilepsy with progressive myoclonus 1 or Baltic myoclonic epilepsy.* This is the most frequent cause of PME worldwide and is associated with a less severe phenotype than seen in other PME.<sup>97</sup> Most cases originate from the Scandinavian or Baltic regions of Europe, or Northern Africa. Prevalence may be as high as 1:20 000 in Finland.<sup>98</sup> The severity of the condition, and therefore life expectancy, vary widely.<sup>97–99</sup> ULD begins before 18 years of age, typically 7–13 years of age,<sup>99</sup> with tonic-clonic or myoclonic seizures; absence seizures can occur. Myoclonus may be induced by tactile or photic stimulation and is usually more pronounced upon waking. It can be significantly worsened by phenytoin.<sup>100</sup> Progression is seen in adolescence, usually beginning in the first 6 years after seizure onset, with worsening of myoclonus, development of ataxia, and mild cognitive decline. The condition tends to stabilize in early adulthood, with minimal or no further cognitive decline, and myoclonus and ataxia may even

**TABLE 10** Core diagnostic criteria for progressive myoclonus epilepsies

	Mandatory	Alert <sup>a</sup>	Exclusionary
Seizures	Myoclonic seizures		
EEG	Generalized spike/polyspike-and-wave		Persistent focal epileptiform abnormality, other than occipital
Age at onset	2–50 years	>20 years	
Development	Normal at onset		
Neurological exam	Normal at onset		
Comorbidities	Progressive neurocognitive deterioration (in some cases observation over time is necessary to distinguish PME from JME)		
Imaging	Normal at onset		
Course of illness	Progressive worsening of myoclonus, myoclonic and generalized tonic-clonic seizures, cognitive decline, progressive cerebellar signs EEG deterioration with progressive background slowing and/or increased epileptiform abnormality		

An MRI is not required for diagnosis but is often done to evaluate for underlying etiology.  
An ictal EEG is not required for diagnosis.

Syndrome without laboratory confirmation: In resource-limited regions, PME can be suspected in persons who meet mandatory and no exclusionary criteria, without alerts, and who show a progressive worsening of myoclonic seizures and neurological and cognitive function.

Abbreviations: EEG, electroencephalogram; JME, juvenile myoclonic epilepsy; MRI, magnetic resonance imaging; PME, progressive myoclonus epilepsies.

<sup>a</sup>Alert criteria are absent in the vast majority of cases, but rarely can be seen. Their presence should result in caution in diagnosing the syndrome and consideration of other conditions.

**TABLE 11** Key characteristics of etiologies of progressive myoclonus epilepsies discussed in this paper

PME type	Age at onset	Progression	Diagnosis
ULD	7–13 years	Slow cognitive and motor deterioration with stabilization in adulthood	Cystatin B ( <i>EMPI</i> ) expansion variations account for ~90% of cases worldwide
LD	6–19 years	Early rapid cognitive, vision, and motor deterioration; fatal approximately a decade after onset; focal seizures with visual symptoms are an early feature	Laforin ( <i>EMP2A</i> ) pathogenic gene variant in 70%, malin ( <i>EMP2B</i> ) pathogenic gene variant in 27%, no pathogenic variant found in 3%; Lafora bodies are seen in sweat duct cells or other tissues
CLN2	2–4 years	Initial speech delay and seizures, subsequently deterioration in cognition and motor skills, and then vision loss emerges at 4–6 years of age	<i>CLN2/TPP1</i> pathogenic gene variants; <i>TPP1</i> enzyme activity is reduced; EEG can show a photoparoxysmal response at low (1–3 Hz) frequency; curvilinear bodies profile of lipofuscin accumulation in tissues (e.g., skin) or lymphocytes
CLN3	4–10 years	Rapidly progressing vision loss, with macular degeneration, optic atrophy ± retinitis pigmentosa; survival: late teens–30 years	<i>CLN3</i> pathogenic gene variants; fingerprint profile of lipofuscin accumulation in tissue (e.g., skin) or lymphocytes; lymphocytes are vacuolated
Adult onset NCL (type A)	11–50 years	Slow development of dementia and ataxia; visual impairment is not expected	<i>CLN6</i> pathogenic gene variants (pathogenic variants in <i>CTSD</i> , <i>PPT1</i> , <i>CLN3</i> , <i>CLN5</i> , <i>CTSF</i> , and <i>GRN</i> also reported); mixed type inclusions (fingerprint, curvilinear, rectilinear) in tissue (e.g., skin) or lymphocytes

Abbreviations: *TPP1*, tripeptidyl-peptidase 1; PME, progressive myoclonus epilepsies; MRI, magnetic resonance imaging; ULD, Unverricht–Lundborg disease; LD, Lafora disease; CLN, ceroid lipofuscinosis; NCL, neuronal ceroid lipofuscinosis; EEG, electroencephalogram.

improve. The EEG background may be normal at onset; progressive slowing of the background usually appears over time. Photic stimulation facilitates spike-and-wave on EEG in most cases<sup>96</sup>; this can be seen early in the condition. Interictal generalized spike- and polyspike-and-wave are seen (Figure 9). EEG during myoclonic seizures shows generalized polyspike-and-wave. MRI is usually normal in the early stages of the condition; later, mild atrophy can be seen. A repeat expansion variation in the cystatin B (*CSTB*, *EMPI*) gene accounts for approximately 90% of the cases worldwide; inheritance is autosomal recessive. The type of pathogenic variant can relate to severity.<sup>99</sup>

#### Lafora disease

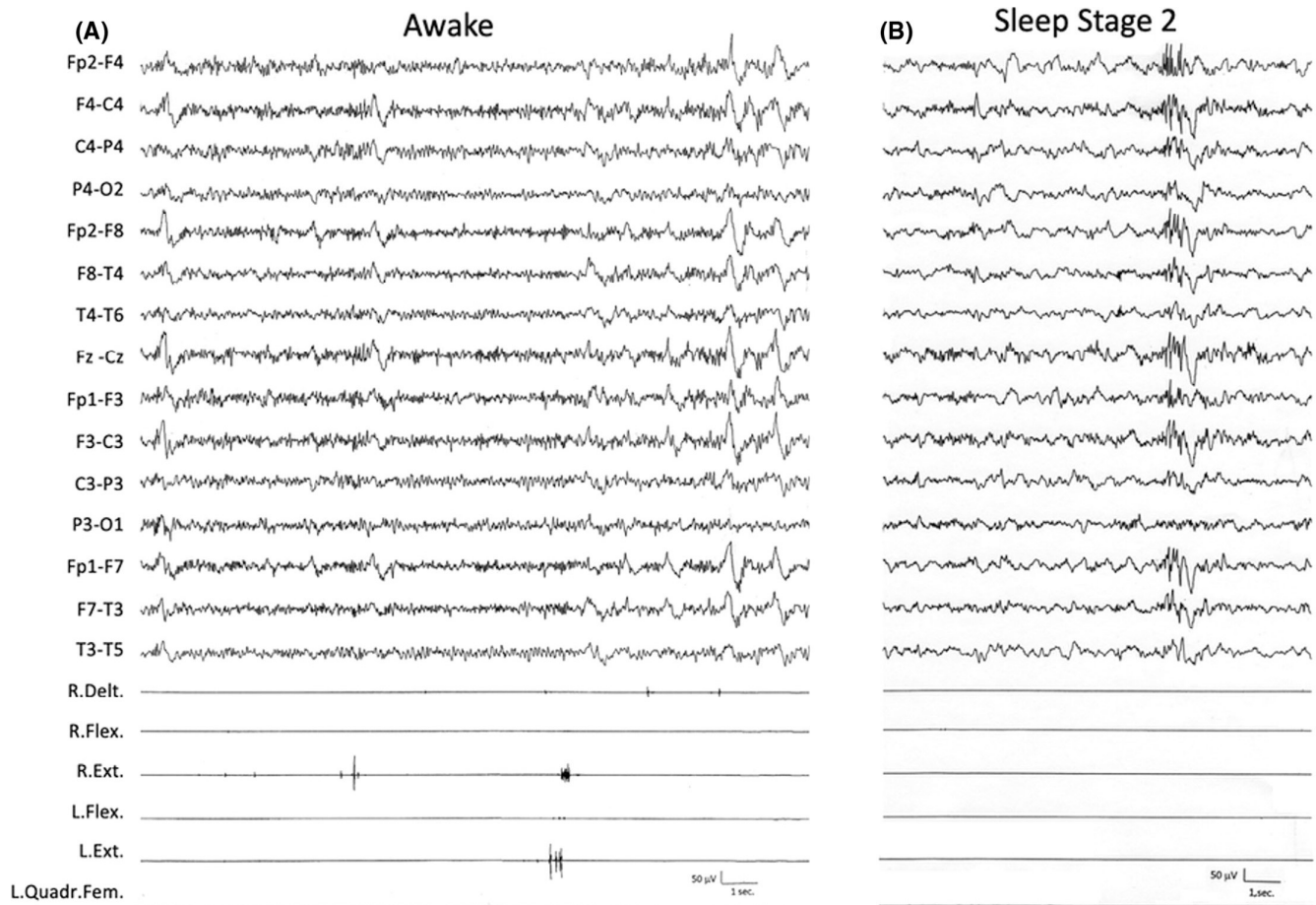
*Also known as Lafora body disease, progressive myoclonic epilepsy 2A and 2B.* Lafora disease is more prevalent in Southern Europe, Northern Africa, and Central and Southern Asia.<sup>101</sup> The disorder is usually fatal approximately 10 years after onset; however, a slowly progressive form has also been described.<sup>102</sup> This subtype of PME begins between 6 and 19 years of age, typically 14–15 years, with cognitive decline, cerebellar signs (ataxia, incoordination), vision loss, and myoclonic and generalized tonic–clonic seizures. Focal seizures with visual symptoms (transient blindness, elemental visual phenomena, or visual hallucination) are characteristically an early manifestation.<sup>101</sup> Myoclonic seizures gradually worsen and become intractable, and progressive cognitive decline continues. By 10 years after onset, affected individuals have nearly continuous myoclonus with absence seizures, frequent generalized tonic–clonic seizures, and profound dementia or are in a vegetative state. At onset, the EEG has a normal background, with interictal spike-and-wave and polyspike discharges that are activated by photic stimulation at low frequencies. In contrast to JME, generalized epileptiform abnormality is not activated in sleep,<sup>101</sup> although focal epileptiform abnormality in the posterior regions can be.<sup>103</sup> With time, the EEG background slows, and epileptiform abnormality increases in frequency and may have emphasis in posterior regions (Figure 10). Patients with Lafora disease can develop erratic myoclonus without EEG correlate, a further distinction from JME. MRI is usually normal, but magnetic resonance spectroscopy may show significant reduction of the N-acetylaspartate/creatine ratio in frontal cortex, basal ganglia, and cerebellar hemispheres.<sup>104</sup> Fluorodeoxyglucose positron emission tomography can show extensive areas of decreased glucose metabolism, the severity of which may correlate with stage of disease.<sup>105</sup> Pathogenic gene variants in *EPM2A* (laforin) and *EPM2B* (malin) are found in 70% and 27% of cases, respectively, with no pathogenic variant found in 3%.<sup>106</sup> Lafora bodies (accumulation of glycogen; Figure 11)

are seen in sweat duct cells and in other tissues.<sup>107</sup> This condition is differentiated from ULD by the presence of early cognitive decline and rapid progression of the PME.

#### NCL

*Also known as Batten disease, ceroid lipofuscinosis.* The NCLs are a group of neurodegenerative lysosomal storage disorders, resulting in excess accumulation of lipopigments (lipofuscin). They were originally classified by age at onset: the infantile onset form ("Finnish form"; not a PME), the late infantile onset form, the juvenile onset form, and the adult onset form. With the identification of causal gene variants, however, the NCLs are now classified according to the underlying pathogenic gene and age at onset. To date, more than a dozen genetically distinct diseases are recognized.<sup>108,109</sup> The diagnosis is based on genetic testing and (in some types) assays of enzyme activity. Electron microscopy of lymphocytes or tissue may be useful for nonclassical presentations. The most prevalent NCLs are:

- Ceroid lipofuscinosis type 2 (CLN2; previously known as NCL type 2, the classic late infantile onset form NCL, and Jansky–Bielschowsky disease). This is the most prevalent NCL and has been reported in different ethnic groups.<sup>110,111</sup> New onset of epilepsy in a child aged 2–4 years, with a history of early language delay, should prompt consideration of CLN2. Multiple seizure types can occur, including febrile, tonic–clonic, absence, myoclonic, atonic, and focal (with or without focal to bilateral tonic–clonic) seizures. Myoclonic seizures may not be present at onset. Delayed speech development is often recognized prior to onset of seizures. Disease progression is often rapid, with loss of mobility and language by the age of 4–5 years. Further regression occurs, with loss of vision occurring over the next few years. Patients die between the ages of 8 and 12 years. EEG may show a photoparoxysmal response at low frequencies of flash stimulation (1–3 Hz; Figure 12)<sup>112</sup>; the spike-and-waves are time-locked to the photic stimuli. MRI shows posterior white matter signal alteration or cerebellar atrophy. Early diagnosis is important in CLN2 disease, because enzyme replacement treatment is available, and this can delay motor and language decline.<sup>113</sup> CLN2 is caused by pathogenic gene variants in the tripeptidyl-peptidase 1 (*TPP1*) *CLN2* gene, resulting in TPP1 enzyme deficiency and subsequent accumulation of lipopigments (lipofuscin) in neurons and other tissues. Variants of late infantile onset NCL may also be caused by pathogenic gene variants in *CLN1*, *CLN5*, *CLN6*, *CLN7*, *CLN8*, and *CTSD*.<sup>108,109</sup>
- CLN3 (previously known as NCL type 3, the classic juvenile onset form NCL, Batten disease, or Spielmeyer–Vogt–Sjögren disease). This is frequent in Scandinavia



**FIGURE 9** Polygraphic recording in a 16-year-old boy with Unverricht–Lundborg disease. (A) In the awake state, abundant fast rhythms (due to benzodiazepines) and bilateral spike-and-sharp-and-wave discharges are seen; on electromyogram (EMG), there are bursts of myoclonic activity without a simultaneous electroencephalographic discharge. (B) In stage 2 sleep, polyspike discharges are seen with an anterior predominance and without myoclonic activity on EMG. L.Ext./R.Ext., left/right arm extensors; L.Flex./R.Flex., left/right arm flexors; L.Quadr.Fem., left quadriceps femoralis; R.Delt., right deltoid

(1% of Swedes carry the gene),<sup>96</sup> but is rare in other regions. This NCL is clinically similar to the late infantile form, but the age at onset is later (4–10 years), and the survival time longer (13–30 years). Visual loss is rapidly progressive, with macular degeneration, optic atrophy, and retinitis pigmentosa.<sup>114</sup> This form is due to pathogenic variants in the *CLN3* gene. The mutant *CLN3* protein retains residual function, explaining why this form of CLN shows later onset and less severe clinical manifestations compared to other forms of CLN.<sup>115</sup> Variants of juvenile NCL may also be caused by pathogenic gene variants in *CLN1*, *CLN2*, *CLN9*, and *ATP13A2*.<sup>108,109</sup>

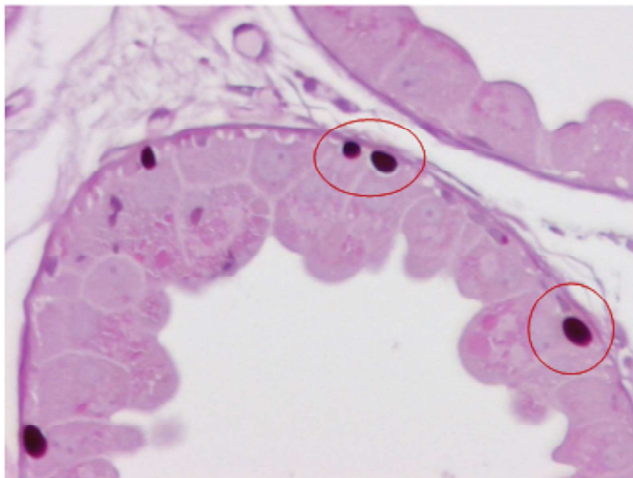
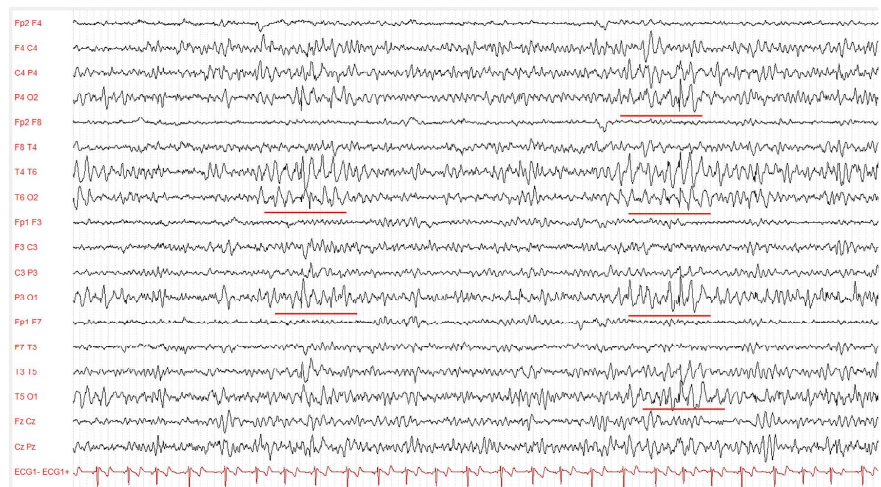
- Adult onset NCL. This NCL (previously known as Kufs disease) is rare and appears as a sporadic condition. It is present in two forms; type A has a PME-like presentation with later development of dementia and ataxia, and type B (not one of the PME) is characterized by dementia with cerebellar or other extrapyramidal motor symptoms. Visual impairment is not expected. Age at

onset is 11–50 years, typically 30 years.<sup>116</sup> The prognosis is poor, with death approximately 10 years after onset. The storage material of lipopigments has different ultrastructural patterns, with mixed combinations of "granular," "curvilinear," and "fingerprint" profiles (Figure 13). This NCL is caused by pathogenic variants in the *CLN6* gene.<sup>117</sup> Variants of adult onset NCL may also be caused by pathogenic gene variants in *CTSD*, *CLN1*, *CLN3*, *CLN5*, *CLN6*, *CTSF*, and *GRN*.<sup>108,109</sup>

### 3 | DISCUSSION

Although not every person with epilepsy can be characterized as having an epilepsy syndrome, identification of a syndrome can provide important guidance on investigation for etiology, management, and prognosis. Syndrome diagnosis relies predominantly on the electroclinical presentation

**FIGURE 10** Electroencephalographic recording in an adult female with Lafora disease showing low-amplitude spikes in the posterior regions (examples underlined)



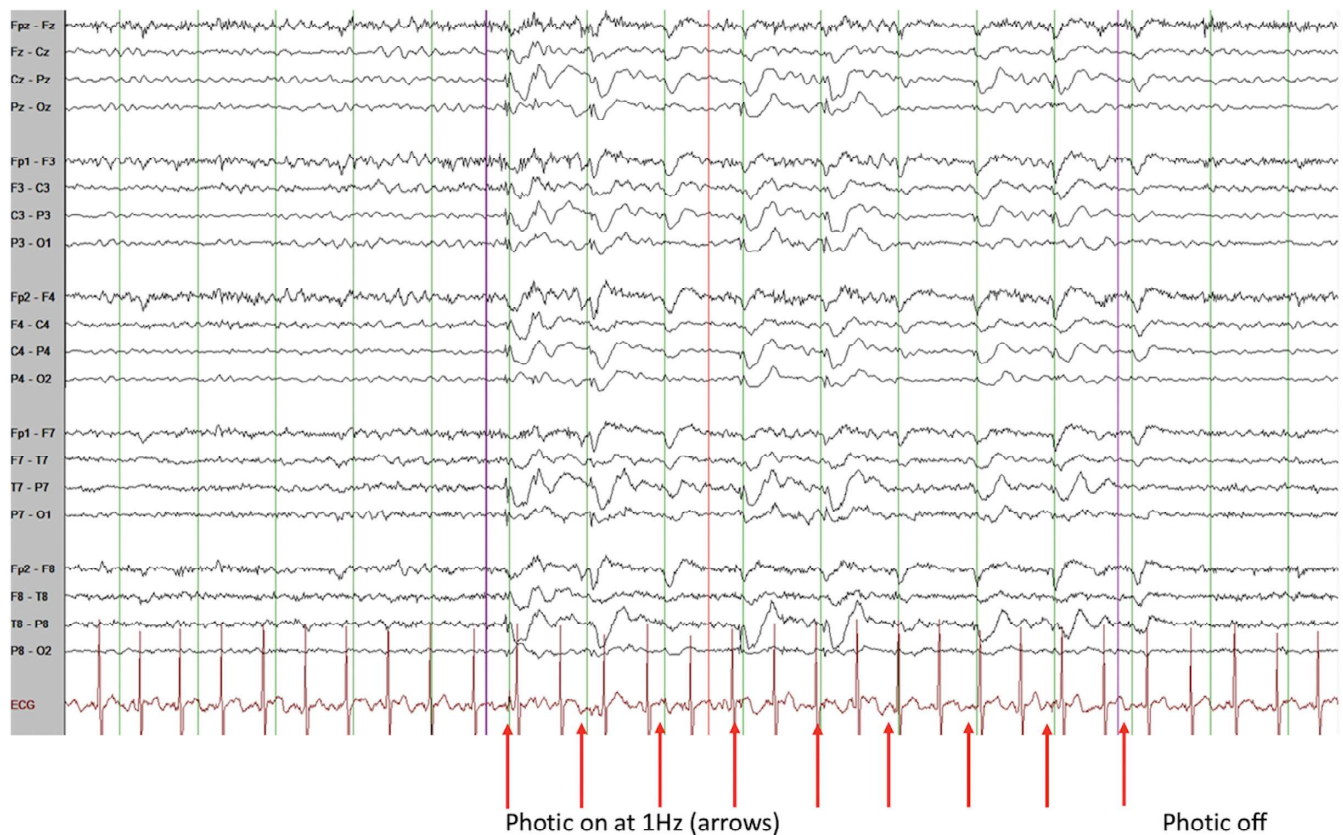**FIGURE 11** Axillary skin biopsy from a patient with Lafora disease. The picture is taken of apocrine gland cells under light microscopy. Intensely periodic acid–Schiff positive material (Lafora bodies) is observed scattered in the cytoplasm of several cells (circles)

with specific seizure types in specific clinical contexts and specific interictal EEG patterns. In the modern era, clinical phenotyping has been enhanced through the use of home video of seizures, allowing clinicians access to details of seizure semiology, often complementing or superior to video obtained during video-EEG.<sup>118</sup> Clinicians may select targeted EEG investigations (awake with photic stimulation, asleep, prolonged, overnight, or with simultaneous polygraphic recording) that assist with confirming the specific epilepsy syndrome. As epilepsy syndrome identification informs likely etiology, the diagnosis of a syndrome allows clinicians to initiate the highest yield, most cost-effective investigations to obtain an etiological diagnosis, limiting discomfort and risk to the patient. Investigating the individual's family history (including clinical, EEG, and imaging phenotypes of every affected member) is essential for the

diagnosis of several focal epilepsy syndromes presenting at a variable age and enhances the assessment of pathogenicity of gene variants identified during genomic investigation, which is increasingly utilized in the current era.

Identifying a syndrome can also inform therapy decisions. Remission of the epilepsy can be expected in most patients with COVE and POLE. A patient with JME can have aggravation of their epilepsy, to mimic PME, when treated with sodium channel blockers (such as carbamazepine).<sup>1</sup> Seizures in PME can be aggravated significantly by sodium channel blockers (such as phenytoin).<sup>100</sup> Although apparently a focal epilepsy, patients with MTLE-HS may rarely have aggravation of their epilepsy with sodium channel blockers, if there is a concomitant sodium channelopathy. Furthermore, for focal epilepsy syndromes (SHE, FMTLE, FFEVF, EAF, MTLE-HS, and RS), epilepsy surgery may be effective if seizures do not respond to ASMs. This includes when there is an underlying genetic–structural etiology (specifically mammalian target of rapamycin [mTOR] pathway genes *TSC1*, *TSC2*, *DEPDC5*, *NPRL2*, and *NPRL3*), but epilepsy surgery has not been associated with seizure freedom in Dravet syndrome-associated MTLE-HS.<sup>77</sup> In this fashion, both the syndrome and etiology are important for tailoring treatment, and counseling regarding candidacy for surgery and likely surgical outcome. Although recognition of autoimmune-associated epilepsies<sup>119</sup> other than RS is important, as their prompt identification allows earlier treatment and improved cognitive outcomes, the literature on these epilepsies (as distinct from autoimmune disorders associated with acute symptomatic/acute provoked seizures) is still emerging. The authors acknowledge that some antibody-specific autoimmune-associated epilepsies may meet criteria for an etiology-specific epilepsy syndrome and that future work will develop the definitions of such syndromes.

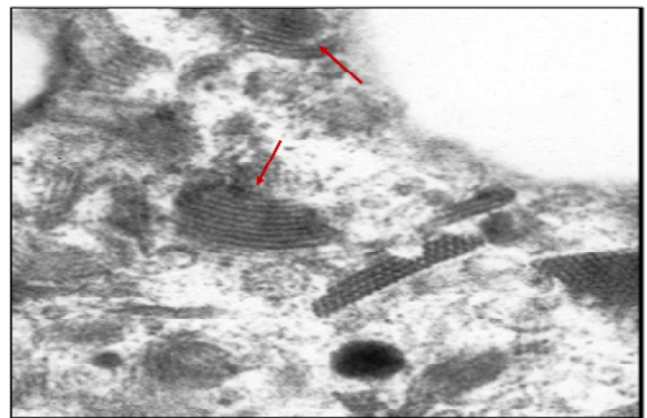
Fortunately, the epilepsy syndromes with DEE and epilepsy syndromes with progressive neurological



**FIGURE 12** Electroencephalogram showing slow photoparoxysmal response to 1-Hz photic stimulation (applied at the time of the arrows in the image) in a child 3 years 9 months old with ceroid lipofuscinosis type 2 disease

deterioration presenting at a variable age are rare, specifically FIRES, RS and PME. In these syndromes, cognitive and neurological impairment are nearly always eventually present. Therapeutic options are limited for these syndromes; for example, hemispheric disconnection in RS, although it resolves the epilepsy, results in a permanent hemispheric neurological deficit. Therapeutic options are limited for many PMEs, although recently enzyme replacement therapy has become available for CLN2.<sup>113</sup> There is a great need for better therapies for these disorders, and their identification is essential to facilitate patients being included in clinical trials.

The definitions of epilepsy syndromes provided in this paper will require validation in longitudinal studies and may be further refined as new data are published over time. Historically, epilepsy syndromes evolved from patients (and families) being grouped into empirically delineated electroclinical presentations, and then research reported data from those cohorts, describing their phenotype (clinical, EEG, imaging) and associated etiologies. This past approach has strongly influenced early characterization of epilepsy syndromes. As time passed, and with contributions from genetic research, the phenotypic spectrum for some syndromes has expanded and etiology-specific epilepsy syndromes are increasingly being characterized.



**FIGURE 13** Typical "fingerprint" inclusion bodies (arrows) in a patient with adult onset neuronal ceroid lipofuscinosis, seen on electron microscopy of a skin biopsy

This is likely to continue, and etiology-specific epilepsy syndromes will become increasingly important. Strict delineation of epilepsy syndromes can be harmful if they exclude patients who do not precisely meet a syndrome's criteria from having appropriate investigation and treatment for the syndrome (and related etiology) that they approximate but do not strictly meet. Syndromes should,

therefore, be revised in the future to reflect expanded phenotypes, or alternatively more restricted phenotypes, when these are recognized as relevant, and to include newly identified etiologies, when these are discovered. This may have importance when specific family planning, preventative, or mitigating interventions are available for the etiology and/or its neurodevelopmental and cognitive sequelae—for example, emerging antiepileptogenesis strategies before onset of seizures in specific mTORopathies.<sup>120</sup> Looking to the future, with ongoing research improving delineation of structural brain abnormalities, immune-mediated pathologies, and pathogenic gene variants, it is likely that more etiology-specific epilepsy syndromes will emerge. However, epilepsy syndromes will continue to have relevance, as the phenotypes associated with some etiologies may not be specific (e.g., *DEPDC5*), and syndrome identification will remain important for targeting investigation toward a group of potential etiologies, guiding treatment, and prognosis counseling. Future work establishing diagnostic criteria for etiology-specific epilepsy syndromes will be important for research into precision therapies (e.g., mTOR inhibitors for mTORopathies: *TSC1*, *TSC2*, *DEPDC5*, *NPRL2*, *NPRL3*), advancing knowledge of pathogenesis and for identifying subgroups within specific etiologies that have a better treatment response. It is anticipated that this will be the role of future Task Forces of the ILAE.

### ACKNOWLEDGMENTS

We gratefully acknowledge the contributions to this final article from wider members of the ILAE Nosology and Definitions Task Force (2017–2021), the ILAE Review Task Force (2021–2022), experts from around the world who contributed to our Delphi methodology, and the wider epilepsy community, who provided comments on a draft of this article posted on the ILAE's website (April–July 2021). We specifically thank:

- ILAE Nosology and Definitions Task Force (2017–2021): Elissa Yozawitz, Helen Cross, Jo Wilmschurst, O. Carter Snead, Ronit Pressler, Sunao Kaneko, Paula Samia.
- ILAE Review Task Force (2021–2022): Chahnez Triki, Fatema Abdulla, Marilissa Guerreiro, Michael Sperling, Sam Gwer, Santiago Galicchio.
- Delphi experts (pediatric): Ana Carolina Coan (Brazil), Angelina Kakooza (Uganda), Charles Newton (Kenya), Eliane Roulet-Perez (Switzerland), Floor Jansen (Netherlands), Helen Yue-Hua Zhang (China), Kelly Knupp (USA), Loreto Rios (Chile), Lieven Lagae (Belgium), Lynette Sadlier (New Zealand), Mary Connolly (Canada), Mitsuhiro Kato (Japan), Raidah Al Baradi (Saudi Arabia), Renee Shellhaas (USA), Roberto Carraballo (Argentina), Thomas Bast (Germany), Vrajesh Udani (India).

- Delphi experts (adult): Ahmed Beydoun (Egypt), Barbara Jobst (USA), Birinus Adikaibe (Nigeria), Christian Bien (Germany), Daniel San Juan-Orta (Mexico), Danielle Andrade (Canada), Dong Zhou (China), John Dunne (Australia), Jose Serratos (Spain), Kurupath Radakrishnan (India), Luis Carlos Mayor (Colombia), Meng-Han Tsai (Taiwan), Natela Okujava (Georgia), Reetta Kaiviainen (Finland), Sammy Ohene (Ghana), Sheryl Haut (USA), Silvia Kochen (Argentina).

### CONFLICT OF INTEREST

K.R. has received honoraria for educational symposia, advisory boards, and/or consultancy work from Eisai, LivaNova, Novartis, and UCB Australia. Her institution has supported clinical trials for Biogen Idec Research, DSLP, Eisai, Epigenyx Therapeutics, GW Research, Janssen-Cilag, Marinus Pharmaceuticals, Medicure International, LivaNova, Neurocrine Biosciences, Noema Pharma, Novartis, SK Lifesciences, UCB Australia, UCB Biopharma, and Zogenix. E.S. reports research support from Eisai, UCB, Zynerva, Marinus, SK Life Sciences, Upsher-Smith, Cerevel, National Health and Medical Research Council of Australia, and Australian Research Council. He has received support for educational activities from Sanofi, UCB, and ILAE. He reports speaker's fees from Eisai and the Epilepsy Consortium and consulting fees from Eisai, UCB, and Seqirus. E.H. has received honoraria from UCB, Eisai, LivaNova, Novartis, and GW Pharmaceuticals. R.N. has served as principal investigator in clinical trials for Novartis, Nutricia, Eisai, UCB, GW Pharma, and LivaNova. She has received consulting fees from Biogene, BioMarin, GW Pharma, Zogenix, Novartis, Nutricia, Stoke, Ionis, Targeon, and Takeda and honoraria from Nutricia, Biocodex, Zogenix, GW Pharma, Advicennes, and Eisai. She has received unrestricted research grants from Eisai, UCB, LivaNova, and GW Pharma and academic research grants from EJP-RD (Horizons 2020) and IDEAL-EPISTOP. I.E.S. has served on scientific advisory boards for UCB, Eisai, GlaxoSmithKline, BioMarin, Nutricia, Rogcon, Chiesi, Encoded Therapeutics, and Xenon Pharmaceuticals; has received speaker honoraria from GlaxoSmithKline, UCB, BioMarin, Biocodex, and Eisai; has received funding for travel from UCB, Biocodex, GlaxoSmithKline, BioMarin, and Eisai; has served as an investigator for Zogenix, Zynerva, Ultragenyx, GW Pharma, UCB, Eisai, Anavex Life Sciences, Ovid Therapeutics, Epigenyx, Encoded Therapeutics, and Marinus; and has consulted for Zynerva Pharmaceuticals, Atheneum Partners, Ovid Therapeutics, Care Beyond Diagnosis, Epilepsy Consortium, and UCB. S.M.Z. has received research support from Epilepsy Research UK, Tenovus Foundation, Glasgow Children's Hospital Charity, and Scottish Government Digital Health & Care. His institution has undertaken commercial trials

for GW Pharma, Zogenix, Stoke Therapeutics, Encoded Therapeutics, and Marinus Pharmaceuticals. He has received honoraria for educational symposia, advisory boards, and consultancy work from GW Pharma, UCB Pharma, Eisai, Zogenix, Arvelle Therapeutics, GRIN Therapeutics, Jaguar Gene Therapeutics, and Encoded Therapeutics. T.A. has received consultation fees from Eli Lilly, Lundbeck, Merck, Hikma, Novartis, and Sanofi, and research support from Novartis and Biogen. J.F. receives NYU salary support from the Epilepsy Foundation and for consulting work and/or attending scientific advisory boards on behalf of the Epilepsy Study Consortium for Adamas, Aeonian/Aeovian, Anavex, Arkin Holdings, Arvelle Therapeutics, Athenen Therapeutics/Carnot Pharma, Baergic Bio, Biogen, BioXcel Therapeutics, Cavion, Cerebral Therapeutics, Cerevel, Crossject, CuroNZ, Eisai, Eliem Therapeutics, Encoded Therapeutics, Engage Therapeutics, Engrail, Epiminder, Equilibre BioPharmaceuticals, Fortress Biotech, Greenwich Biosciences, GW Pharma, Janssen Pharmaceutica, Knopp Biosciences, Lundbeck, Marinus, Mend Neuroscience, Merck, NeuCyte, Neurocrine, Otsuka Pharmaceutical Development, Ovid Therapeutics, Passage Bio, Praxis, Redpin, Sage, SK Life Sciences, Sofinnova, Stoke, Supernus, Synergia Medical, Takeda, UCB, West Therapeutic Development, Xenon, Xeris, Zogenix, and Zynerva. J.F. has also received research support from the Epilepsy Research Foundation, Epilepsy Study Consortium (funded by Andrews Foundation, Eisai, Engage, Lundbeck, Pfizer, SK Life Science, Sunovion, UCB, and Vogelstein Foundation), Epilepsy Study Consortium/Epilepsy Foundation (funded by UCB, Engage, Neurelis, SK Life Science), GW/One8 Foundation/FACES, and NINDS. She is on the editorial board of *Lancet Neurology* and *Neurology Today*. She is Chief Medical/Innovation Officer for the Epilepsy Foundation, for which NYU receives salary support. She has received travel reimbursement related to research, advisory meetings, or presentation of results at scientific meetings from the Epilepsy Study Consortium, the Epilepsy Foundation, Arvelle Therapeutics, Biogen, Cerevel, Engage, Lundbeck, NeuCyte, Otsuka, Sage, UCB, Xenon, and Zogenix. N.S. has served on scientific advisory boards for GW Pharma, BioMarin, Arvelle, Marinus, and Takeda; has received speaker honoraria from Eisai, BioMarin, LivaNova, and Sanofi; and has served as an investigator for Zogenix, Marinus, BioMarin, UCB, and Roche. E.T. reports personal fees from EVER Pharma, Marinus, Argenix, Arvelle, Angelini, Medtronic, Bial-Portela & Ca, NewBridge, GL Pharma, GlaxoSmithKline, Hikma, Boehringer Ingelheim, LivaNova, Eisai, UCB, Biogen, Genzyme Sanofi, GW Pharmaceuticals, and Actavis; his institution received grants from Biogen, UCB Pharma, Eisai, Red Bull, Merck, Bayer, the European Union, FWF Österreichischer Fond zur Wissenschaftsförderung,












Bundesministerium für Wissenschaft und Forschung, and Jubiläumsfond der Österreichischen Nationalbank outside the submitted work. S.W. has received research support from the Canadian Institutes of Health Research and Alberta Innovates Health Solutions. He chairs the Clinical Research Unit at the University of Calgary, which receives support from the Cumming School of Medicine. His institution has received unrestricted educational grants from UCB Pharma, Eisai, and Sunovion. S.A. has served as a consultant for or received honoraria for lectures from Biocodex, BioMarin, Eisai, GW Pharma, Neuraxpharm, Nutricia, UCB Pharma, Xenon, and Zogenix. He has been an investigator for clinical trials for Eisai, UCB Pharma, and Zogenix. He is an Associate Editor for *Epilepsia*. A.N. has received speaker or writer honoraria from Sanofi, Genzyme Sanofi, Ann Lake Publications, and Novartis. She has received research funding from the University of KwaZulu Natal and the KM Browse Scholarship. The unit at Greys Hospital or its members have received educational or travel support from National Bioproducts Institute, Boehringer Ingelheim, Allergan, and Equity Pharmaceuticals. E.P. has received speaker and/or consultancy fees from Angelini, Arvelle, Biogen, Biopas, Eisai, GW Pharma, Sanofi group of companies, SK Life Science, Takeda, UCB Pharma, Xenon Pharma, and Zogenix. He has also received royalties from Wiley, Elsevier, and Wolters Kluwer. S.L.M. is the Charles Frost Chair in Neurosurgery and Neurology and acknowledges grant support from the National Institutes of Health (U54 NS100064 and NS43209), US Department of Defense (W81XWH-18-1-0612), Heffer Family and Segal Family Foundations, and Abbe Goldstein/Joshua Lurie and Laurie Marsh/Dan Levitz families. S.L.M. is serving as Associate Editor of *Neurobiology of Disease*. He is on the editorial board of *Brain and Development*, *Pediatric Neurology*, *Annals of Neurology*, *MedLink*, and *Physiological Research*. He receives compensation from Elsevier for his work as an Associate Editor of *Neurobiology of Disease* and from *MedLink* for his work as an Associate Editor; and royalties from two books he coedited. E.C.W. has served as a paid consultant for Encoded Therapeutics and BioMarin. She is the Editor-in-Chief of *Epilepsy.com*. P.T. has received speaker's or consultancy fees from Arvelle, Eisai, GW Pharma, LivaNova, UCB Pharma, Xenon Pharma, and Zogenix. None of the other authors has any conflict of interest to disclose. We confirm that we have read the Journal's position on issues involved in ethical publication and affirm that this report is consistent with those guidelines.

#### ORCID

Kate Riney  <https://orcid.org/0000-0002-1122-3555>

Ernest Somerville  <https://orcid.org/0000-0001-8789-1122>

Edouard Hirsch  <https://orcid.org/0000-0003-0833-8850>

Rima Nabhout  <https://orcid.org/0000-0001-5877-4074>  
 Ingrid E. Scheffer  <https://orcid.org/0000-0002-2311-2174>  
 Taoufik Alsaadi  <https://orcid.org/0000-0002-7513-5706>  
 Jacqueline French  <https://orcid.org/0000-0003-2242-8027>  
 Nicola Specchio  <https://orcid.org/0000-0002-8120-0287>  
 Eugen Trinka  <https://orcid.org/0000-0002-5950-2692>  
 Samuel Wiebe  <https://orcid.org/0000-0002-1061-9099>  
 Stéphane Auvin  <https://orcid.org/0000-0003-3874-9749>  
 Emilio Perucca  <https://orcid.org/0000-0001-8703-223X>  
 Solomon L. Moshé  <https://orcid.org/0000-0001-9427-9476>  
 Elaine C. Wirrell  <https://orcid.org/0000-0003-3015-8282>

## REFERENCES

- Wirrell EC, Nabhout R, Scheffer IE, Alsaadi T, Bogacz A, French J, et al. Methodology for classification and definition of epilepsy syndromes with list of syndromes: report of the ILAE Task Force on Nosology and Definitions. *Epilepsia*. In press.
- Zuberi SM, Wirrell E, Yozawitz E, Wilmshurst J, Specchio N, Riney K, et al. ILAE classification and definition of epilepsy syndromes in the neonate and infant: position statement by the ILAE Task Force on Nosology and Definitions. *Epilepsia*. In press.
- Specchio N, Wirrell EC, Scheffer IE, Nabhout R, Riney K, Samia P, et al. ILAE classification and definition of epilepsy syndromes with onset in childhood: position statement by the ILAE Task Force on Nosology and Definitions. *Epilepsia*. In press.
- Hirsch E, French J, Scheffer IE, Bogacz A, Alsaadi T, Sperling M, et al. ILAE definition of idiopathic generalized epilepsy syndromes: position statement by the ILAE Task Force on Nosology and Definitions. *Epilepsia*. In press.
- Richards S, Aziz N, Bale S, Bick D, Das S, Gastier-Foster J, et al. Standards and guidelines for the interpretation of sequence variants: a joint consensus recommendation of the American College of Medical Genetics and Genomics and the Association for Molecular Pathology. *Genet Med*. 2015;17(5):405–24. <https://doi.org/https://doi.org/10.1038/gim.2015.30>
- Jallon P, Latour P. Epidemiology of idiopathic generalized epilepsies. *Epilepsia*. 2005;46(Suppl 9):10–4.
- Gastaut H, Zifkin BG. Benign epilepsy of childhood with occipital spike and wave complexes. In: Andermann F, Lugaresi E, editors. *Migraine and epilepsy*. Boston, MA: Butterworths; 1987. p. 47–81.
- Gastaut H, Roger J, Bureau M. Benign epilepsy of childhood with occipital paroxysms. In: Roger J, Bureau M, Dravet C, Dreifuss F, Perret A, Wolf P, editors. *Epileptic syndromes in infancy, childhood and adolescence*. 2nd ed. London, UK: John Libbey & Company; 1992. p. 201–17.
- Caraballo RH, Cersósimo RO, Fejerman N. Childhood occipital epilepsy of Gastaut: a study of 33 patients. *Epilepsia*. 2008;49(2):288–97.
- Koutroumanidis M, Tsirka V, Panayiotopoulos C. Adult-onset photosensitivity: clinical significance and epilepsy syndromes including idiopathic (possibly genetic) photosensitive occipital epilepsy. *Epileptic Disord*. 2015;17(3):275–86.
- Berg AT, Berkovic SF, Brodie MJ, Buchhalter J, Cross JH, van Emde Boas W, et al. Revised terminology and concepts for organization of seizures and epilepsies: report of the ILAE Commission on Classification and Terminology, 2005–2009. *Epilepsia*. 2010;51:676–85.
- Scheffer IE, Phillips HA, O'Brien CE, Saling MM, Wrennall JA, Wallace RH, et al. Familial partial epilepsy with variable foci: a new partial epilepsy syndrome with suggestion of linkage to chromosome 2. *Ann Neurol*. 1998;44:890–9.
- Provini F, Plazzi G, Tinuper P, Vandi S, Lugaresi E, Montagna P. Nocturnal frontal lobe epilepsy. A clinical and polygraphic overview of 100 consecutive cases. *Brain*. 1999;122(Pt 6):1017–31.
- Berkovic SF, Serratos JM, Phillips HA, Xiong L, Andermann E, Diaz-Otero F, et al. Familial partial epilepsy with variable foci: clinical features and linkage to chromosome 22q12. *Epilepsia*. 2004;45:1054–60.
- Licchetta L, Pippucci T, Baldassari S, Minardi R, Provini F, Mostacci B, et al. Sleep-related hypermotor epilepsy (SHE): contribution of known genes in 103 patients. *Seizure*. 2020;74:60–4.
- Scheffer IE, Heron SE, Regan BM, Mandelstam S, Crompton DE, Hodgson BL, et al. Mutations in mammalian target of rapamycin regulator DEPDC5 cause focal epilepsy with brain malformations. *Ann Neurol*. 2014;75:782–7.
- Picard F, Makrythanasis P, Navarro V, Ishida S, de Bellescize J, Ville D, et al. DEPDC5 mutations in families presenting as autosomal dominant nocturnal frontal lobe epilepsy. *Neurology*. 2014;10(82):2101–6.
- Ricos MG, Hodgson BL, Pippucci T, Saidin A, Ong YS, Heron SE, et al. Mutations in the mammalian target of rapamycin pathway regulators NPRL2 and NPRL3 cause focal epilepsy. *Ann Neurol*. 2016;79:120–31.
- Korenke GC, Eggert M, Thiele H, Nürnberg P, Sander T, Steinlein OK. Nocturnal frontal lobe epilepsy caused by a mutation in the GATOR1 complex gene NPRL3. *Epilepsia*. 2016;57:e60–3.
- Tinuper P, Bisulli F, Cross JH, Hesdorffer D, Kahane P, Nobili L, et al. Definition and diagnostic criteria of sleep-related hypermotor epilepsy. *Neurology*. 2016;10(86):1834–42.
- Licchetta L, Bisulli F, Vignatelli L, Zenesini C, Di Vito L, Mostacci B, et al. Sleep-related hypermotor epilepsy: long-term outcome in a large cohort. *Neurology*. 2017;3(88):70–7.
- Vignatelli L, Bisulli F, Giovannini G, Licchetta L, Naldi I, Mostacci B, et al. Prevalence of sleep-related hypermotor epilepsy—formerly named nocturnal frontal lobe epilepsy—in the adult population of the Emilia-Romagna region, Italy. *Sleep*. 2017;1:40.
- Licchetta L, Poda R, Vignatelli L, Pippucci T, Zenesini C, Menghi V, et al. Profile of neuropsychological impairment in sleep-related hypermotor epilepsy. *Sleep Med*. 2018;48:8–15.
- Gibbs SA, Proserpio P, Francione S, Mai R, Cardinale F, Sartori I, et al. Clinical features of sleep-related hypermotor epilepsy in relation to the seizure-onset zone: a review of 135 surgically treated cases. *Epilepsia*. 2019;60:707–17.
- Fisher RS, Cross JH, French JA, Higurashi N, Hirsch E, Jansen FE, et al. Operational classification of seizure types by the International League Against Epilepsy: position paper of the ILAE Commission for Classification and Terminology. *Epilepsia*. 2017;58:522–30.
- Scheffer IE, Bhatia KP, Lopes-Cendes I, Fish DR, Marsden CD, Andermann E, et al. Autosomal dominant nocturnal frontal lobe epilepsy. A distinctive clinical disorder. *Brain*. 1995;118(Pt 1):61–73.
- Oldani A, Zucconi M, Asselta R, Modugno M, Bonati MT, Dalprà L, et al. Autosomal dominant nocturnal frontal lobe

- epilepsy. A video-polysomnographic and genetic appraisal of 40 patients and delineation of the epileptic syndrome. *Brain*. 1998;121(Pt 2):205–23.
28. Heron SE, Smith KR, Bahlo M, Nobili L, Kahana E, Licchetta L, et al. Missense mutations in the sodium-gated potassium channel gene *KCNT1* cause severe autosomal dominant nocturnal frontal lobe epilepsy. *Nat Genet*. 2012;44:1188–90.
  29. Derry CP, Heron SE, Phillips F, Howell S, MacMahon J, Phillips HA, et al. Severe autosomal dominant nocturnal frontal lobe epilepsy associated with psychiatric disorders and intellectual disability. *Epilepsia*. 2008;49:2125–9.
  30. Perucca P. Genetics of focal epilepsies: what do we know and where are we heading? *Epilepsy Curr*. 2018;18:356–62.
  31. Losurdo A, Proserpio P, Cardinale F, Gozzo F, Tassi L, Mai R, et al. Drug-resistant focal sleep related epilepsy: results and predictors of surgical outcome. *Epilepsy Res*. 2014;108(5):953–62.
  32. Ryvlin P, Minotti L, Demarquay G, Hirsch E, Arzimanoglou A, Hoffman D, et al. Nocturnal hypermotor seizures, suggesting frontal lobe epilepsy, can originate in the insula. *Epilepsia*. 2006;47:755–65.
  33. Nobili L, Francione S, Mai R, Cardinale F, Castana L, Tassi L, et al. Surgical treatment of drug-resistant nocturnal frontal lobe epilepsy. *Brain*. 2007;130:561–73.
  34. Proserpio P, Cossu M, Francione S, Tassi L, Mai R, Didato G, et al. Insular-opercular seizures manifesting with sleep-related paroxysmal motor behaviors: a stereo-EEG study. *Epilepsia*. 2011;52:1781–91.
  35. Steinlein OK, Mulley JC, Propping P, Wallace RH, Phillips HA, Sutherland GR, et al. A missense mutation in the neuronal nicotinic acetylcholine receptor alpha 4 subunit is associated with autosomal dominant nocturnal frontal lobe epilepsy. *Nat Genet*. 1995;11:201–3.
  36. De Fusco M, Becchetti A, Patrignani A, Annesi G, Gambardella A, Quattrone A, et al. The nicotinic receptor beta 2 subunit is mutant in nocturnal frontal lobe epilepsy. *Nat Genet*. 2000;26:275–6.
  37. Aridon P, Marini C, Di Resta C, Brilli E, De Fusco M, Politi F, et al. Increased sensitivity of the neuronal nicotinic receptor alpha 2 subunit causes familial epilepsy with nocturnal wandering and ictal fear. *Am J Hum Genet*. 2006;79:342–50.
  38. Hildebrand MS, Tankard R, Gazina EV, Damiano JA, Lawrence KM, Dahl HH, et al. *PRIMA1* mutation: a new cause of nocturnal frontal lobe epilepsy. *Ann Clin Transl Neurol*. 2015;2:821–30.
  39. Scheffer IE, Bhatia KP, Lopes-Cendes I, Fish DR, Marsden CD, Andermann F, et al. Autosomal dominant frontal epilepsy misdiagnosed as sleep disorder. *Lancet*. 1994;26(343):515–7.
  40. Crompton DE, Scheffer IE, Taylor I, Cook MJ, McKelvie PA, Vears DF, et al. Familial mesial temporal lobe epilepsy: a benign epilepsy syndrome showing complex inheritance. *Brain*. 2010;133:3221–31.
  41. Kobayashi E, Lopes-Cendes I, Guerreiro CA, Sousa SC, Guerreiro MM, Cendes F. Seizure outcome and hippocampal atrophy in familial mesial temporal lobe epilepsy. *Neurology*. 2001;23(56):166–72.
  42. Cendes F, Lopes-Cendes I, Andermann E, Andermann F. Familial temporal lobe epilepsy: a clinically heterogeneous syndrome. *Neurology*. 1998;50:554–7.
  43. Perucca P, Crompton DE, Bellows ST, McIntosh AM, Kalincik T, Newton MR, et al. Familial mesial temporal lobe epilepsy and the borderland of déjà vu. *Ann Neurol*. 2017;82:166–76.
  44. Berkovic SF, McIntosh A, Howell RA, Mitchell A, Sheffield LJ, Hopper JL. Familial temporal lobe epilepsy: a common disorder identified in twins. *Ann Neurol*. 1996;40:227–35.
  45. Cvetkovska E, Kuzmanovski I, Babunovska M, Boshkovski B, Cangovska TC, Trencavska GK. Phenotypic spectrum in families with mesial temporal lobe epilepsy probands. *Seizure*. 2018;58:13–6.
  46. Morita ME, Yasuda CL, Betting LE, Pacagnella D, Conz L, Barbosa PH, et al. MRI and EEG as long-term seizure outcome predictors in familial mesial temporal lobe epilepsy. *Neurology*. 2012;79:2349.
  47. Kobayashi E, D'Agostino MD, Lopes-Cendes I, Andermann E, Dubeau F, Guerreiro CAM, et al. Outcome of surgical treatment in familial mesial temporal lobe epilepsy. *Epilepsia*. 2003;44:1080–4.
  48. Striano P, Serioli E, Santulli L, Manna I, Labate A, Dazzo E, et al. *DEPDC5* mutations are not a frequent cause of familial temporal lobe epilepsy. *Epilepsia*. 2015;56:e168–71.
  49. Callenbach PMC, Van Den Maagdenberg AMJM, Hottenga JJ, Van Den Boogerd EH, De Coo RFM, Lindhout D, et al. Familial partial epilepsy with variable foci in a Dutch family: clinical characteristics and confirmation of linkage to chromosome 22q. *Epilepsia*. 2003;44:1298–305.
  50. Klein KM, O'Brien TJ, Praveen K, Heron SE, Mulley JC, Foote S, et al. Familial focal epilepsy with variable foci mapped to chromosome 22q12: expansion of the phenotypic spectrum. *Epilepsia*. 2012;53:e151–5.
  51. Picard F, Baulac S, Kahane P, Hirsch E, Sebastianelli R, Thomas P, et al. Dominant partial epilepsies. a clinical, electrophysiological and genetic study of 19 European families. *Brain*. 2000;123(Pt 6):1247–62.
  52. Baulac S, Ishida S, Marsan E, Miquel C, Biraben A, Nguyen DK, et al. Familial focal epilepsy with focal cortical dysplasia due to *DEPDC5* mutations. *Ann Neurol*. 2015;77:675–83.
  53. Dibbens LM, de Vries B, Donatello S, Heron SE, Hodgson BL, Chintawar S, et al. Mutations in *DEPDC5* cause familial focal epilepsy with variable foci. *Nat Genet*. 2013;45:546–51.
  54. Bisulli F, Menghi V, Vignatelli L, Licchetta L, Zenesini C, Stipa C, et al. Epilepsy with auditory features: long-term outcome and predictors of terminal remission. *Epilepsia*. 2018;59:834–43.
  55. Kobayashi E, Santos NF, Torres FR, Scocolin R, Sardinha LAC, Lopez-Cendes I, et al. Magnetic resonance imaging abnormalities in familial temporal lobe epilepsy with auditory auras. *Arch Neurol*. 2003;60:1546–51.
  56. Winawer MR, Ottman R, Hauser WA, Pedley TA. Autosomal dominant partial epilepsy with auditory features: defining the phenotype. *Neurology*. 2000;13(54):2173–6.
  57. Michelucci R, Pulitano P, Di Bonaventura C, Binelli S, Luisi C, Pasini E, et al. The clinical phenotype of autosomal dominant lateral temporal lobe epilepsy related to *reelin* mutations. *Epilepsy Behav*. 2017;68:103–7.
  58. Fanciulli M, Santulli L, Errichiello L, Barozzi C, Tomasi L, Rigon L, et al. *LG11* microdeletion in autosomal dominant lateral temporal epilepsy. *Neurology*. 2012;24(78):1299–303.
  59. Dazzo E, Rehberg K, Michelucci R, Passarelli D, Boniver C, Vianello Dri V, et al. Mutations in *MICAL-1* cause

- autosomal-dominant lateral temporal epilepsy. *Ann Neurol*. 2018;83:483–93.
60. Dazzo E, Fanciulli M, Serioli E, Minervini G, Pulitano P, Binelli S, et al. Heterozygous reelin mutations cause autosomal-dominant lateral temporal epilepsy. *Am J Hum Genet*. 2015;4(96):992–1000.
  61. Pippucci T, Licchetta L, Baldassari S, Palombo F, Menghi V, D'Aurizio R, et al. Epilepsy with auditory features: a heterogeneous clinico-molecular disease. *Neurol Genet*. 2015;1:e5.
  62. Hauser WA, Kurland LT. The epidemiology of epilepsy in Rochester, Minnesota, 1935 through 1967. *Epilepsia*. 1975;16:1–66.
  63. Asadi-Pooya AA, Stewart GR, Abrams DJ, Sharan A. Prevalence and incidence of drug-resistant mesial temporal lobe epilepsy in the United States. *World Neurosurg*. 2017;99:662–6.
  64. Cascino GD, Luckstein RR, Sharbrough FW, Jack CR Jr. Facial asymmetry, hippocampal pathology, and remote symptomatic seizures: a temporal lobe epileptic syndrome. *Neurology*. 1993;43:725–7.
  65. Lewis DV, Shinnar S, Hesdorffer DC, Bagiella E, Bello JA, Chan S, et al. Hippocampal sclerosis after febrile status epilepticus: the FEBSTAT study. *Ann Neurol*. 2014;75:178–85.
  66. Mathern GW, Pretorius JK, Babb TL. Influence of the type of initial precipitating injury and at what age it occurs on course and outcome in patients with temporal lobe seizures. *J Neurosurg*. 1995;82:220–7.
  67. Davies KG, Hermann BP, Dohan FC Jr, Foley KT, Bush AJ, Wyler AR. Relationship of hippocampal sclerosis to duration and age of onset of epilepsy, and childhood febrile seizures in temporal lobectomy patients. *Epilepsy Res*. 1996;24:119–26.
  68. Lewis DV. Febrile convulsions and mesial temporal sclerosis. *Curr Opin Neurol*. 1999;12:197–201.
  69. Bleasel A, Kotagal P, Kankirawatana P, Rybicki L. Lateralizing value and semiology of ictal limb posturing and version in temporal lobe and extratemporal epilepsy. *Epilepsia*. 1997;38:168–74.
  70. Dupont S, Samson Y, Nguyen-Michel V-H, Zavanone C, Navarro V, Baulac M, et al. Lateralizing value of semiology in medial temporal lobe epilepsy. *Acta Neurol Scand*. 2015;132:401–9.
  71. Fakhoury T, Abou-Khalil B. Association of ipsilateral head turning and dystonia in temporal lobe seizures. *Epilepsia*. 1995;36(11):1065–70.
  72. Gambardella A, Gotman J, Cendes F, Andermann F. Focal intermittent delta activity in patients with mesiotemporal atrophy: a reliable marker of the epileptogenic focus. *Epilepsia*. 1995;36(2):122–9.
  73. Miley CE, Forster FM. Activation of partial complex seizures by hyperventilation. *Arch Neurol*. 1977;34:371–3.
  74. Salanova V, Markand O, Worth R. Temporal lobe epilepsy: analysis of patients with dual pathology. *Acta Neurol Scand*. 2004;109:126–31.
  75. Mehvari Habibabadi J, Badihian S, Tabrizi N, Manouchehri N, Zare M, Basiratnia R, et al. Evaluation of dual pathology among drug-resistant epileptic patients with hippocampal sclerosis. *Neurol Sci*. 2019;40:495–502.
  76. Blümcke I, Thom M, Aronica E, Armstrong DD, Vinters HV, Palmini A, et al. The clinicopathologic spectrum of focal cortical dysplasias: a consensus classification proposed by an ad hoc Task Force of the ILAE Diagnostic Methods Commission. *Epilepsia*. 2011;52:158–74.
  77. Stevelink R, Sanders MWCB, Tuinman MP, Brilstra EH, Koeleman BPC, Jansen FE, et al. Epilepsy surgery for patients with genetic refractory epilepsy: a systematic review. *Epileptic Disord*. 2018;1(20):99–115.
  78. Olson HE, Lechpammer M, Prabhu SP, Ciarlini PDSC, Poduri A, Gooty VD, et al. Clinical application and evaluation of the Bien diagnostic criteria for Rasmussen encephalitis. *Epilepsia*. 2013;54:1753–60.
  79. Bien CG, Granata T, Antozzi C, Cross JH, Dulac O, Kurthen M, et al. Pathogenesis, diagnosis and treatment of Rasmussen encephalitis: a European consensus statement. *Brain*. 2005;128:454–71.
  80. Bien CG, Tiemeier H, Sassen R, Kuczaty S, Urbach H, von Lehe M, et al. Rasmussen encephalitis: incidence and course under randomized therapy with tacrolimus or intravenous immunoglobulins. *Epilepsia*. 2013;54:543–50.
  81. Lamb K, Scott WJ, Mensah A, Robinson R, Varadkar S, Cross J. Prevalence and clinical outcome of Rasmussen encephalitis in children from the United Kingdom. *Dev Med Child Neurol*. 2013;55:14.
  82. Varadkar S, Bien CG, Kruse CA, Jensen FE, Bauer J, Pardo CA, et al. Rasmussen's encephalitis: clinical features, pathobiology, and treatment advances. *Lancet Neurol*. 2014;13:195–205.
  83. Oguni H, Andermann F, Rasmussen TB. The syndrome of chronic encephalitis and epilepsy. A study based on the MNI series of 48 cases. *Adv Neurol*. 1992;57:419–33.
  84. Dupont S, Gales A, Sammei S, Vidailhet M, Lambrecq V. Late-onset Rasmussen encephalitis: a literature appraisal. *Autoimmun Rev*. 2017;16:803–10.
  85. Prayson RA. Dual pathology in Rasmussen's encephalitis: a report of coexistent focal cortical dysplasia and review of the literature. *Case Rep Pathol*. 2012;2012:569170.
  86. Chiapparini L, Granata T, Farina L, Ciceri E, Erbetta A, Ragona F, et al. Diagnostic imaging in 13 cases of Rasmussen's encephalitis: can early MRI suggest the diagnosis? *Neuroradiology*. 2003;45:171–83.
  87. Radhakrishnan K, Silbert PL, Klass DW. Reading epilepsy. An appraisal of 20 patients diagnosed at the Mayo Clinic, Rochester, Minnesota, between 1949 and 1989, and delineation of the epileptic syndrome. *Brain*. 1995;118 (Pt 1):75–89.
  88. Haykal MA, El-Feki A, Sonmez Turk HH, Abou-Khalil BW. New observations in primary and secondary reading epilepsy: excellent response to levetiracetam and early spontaneous remission. *Epilepsy Behav*. 2012;23:466–70.
  89. Miller S, Razvi S, Russell A. Reading epilepsy. *Pract Neurol*. 2010;10:278–81.
  90. Valenti MP, Rudolf G, Carre S, Vrielynck P, Thibault A, Szepetowski P, et al. Language-induced epilepsy, acquired stuttering, and idiopathic generalized epilepsy: phenotypic study of one family. *Epilepsia*. 2006;47:766–72.
  91. Wolf P. Reading epilepsy. In: Roger J, Bureau M, Dravet C, Dreifuss FE, Perret A, Wolf P, editors. *Epileptic syndromes in infancy, childhood and adolescence*. 2nd ed. London, UK: John Libbey; 1992. p. 281–98.
  92. Millichap JG. Reading epilepsy response to anticonvulsants. *Pediatr Neurol Briefs*. 2012;26:39–40.
  93. Striano P, Striano S. Reading epilepsy and its variants: a model for system epilepsy. *Epilepsy Behav*. 2011;20:591.
  94. Ferlazzo E, Zifkin BG, Andermann E, Andermann F. Cortical triggers in generalized reflex seizures and epilepsies. *Brain*. 2005;128:700–10.

95. Koutroumanidis M, Koepp MJ, Richardson MP, Camfield C, Agathonikou A, Ried S, et al. The variants of reading epilepsy. A clinical and video-EEG study of 17 patients with reading-induced seizures. *Brain*. 1998;121(Pt 8):1409–27.
96. Genton P, Delgado-Escueta AV, Serratosa JM, Bureau M. Chapter 33: Progressive myoclonus epilepsies. In: Bureau M, Genton P, Dravet C, Delgado-Escueta AV, Tassinari CA, Thomas P, editors. *Epileptic syndromes in infancy, childhood and adolescence*. 5th ed. London, UK: John Libbey Eurotext; 2012. p. 575–606.
97. Magaúdda A, Ferlazzo E, Nguyen VH, Genton P. Unverricht-Lundborg disease, a condition with self-limited progression: long-term follow-up of 20 patients. *Epilepsia*. 2006;47:860–6.
98. Norio R, Koskiniemi M. Progressive myoclonus epilepsy: genetic and nosological aspects with special reference to 107 Finnish patients. *Clin Genet*. 1979;15:382–98.
99. Hyppönen J, Aikia M, Joensuu T, Julkunen P, Danner N, Koskenkorva P, et al. Refining the phenotype of Unverricht-Lundborg disease (EPM1): a population-wide Finnish study. *Neurology*. 2015;14(84):1529–36.
100. Ferlazzo E, Trenite D-N, Haan G-J, Felix Nitschke F, Ahonen S, Gasparini S, et al. Update on pharmacological treatment of progressive myoclonus epilepsies. *Curr Pharm Des*. 2017;23:5662–6.
101. Turnbull J, Tiberia E, Striano P, Genton P, Carpenter S, Ackerley CA, et al. Lafora disease. *Epileptic Disord*. 2016;1(18):38–62.
102. Ferlazzo E, Canafoglia L, Michelucci R, Gambardella A, Gennaro E, Pasini E, et al. Mild Lafora disease: clinical, neurophysiologic, and genetic findings. *Epilepsia*. 2014;55:e129–33.
103. Tassinari CA, Bureau-Paillas M, Dalla Bernardina B, Picornell-Darder I, Mouren MC, Dravet C, et al. La maladie de lafora. *Rev Electroencephalogr Neurophysiol Clin*. 1978;8(1):107–22.
104. Villanueva V, Alvarez-Linera J, Gómez-Garre P, Gutiérrez J, Serratosa JM. MRI volumetry and proton MR spectroscopy of the brain in Lafora disease. *Epilepsia*. 2006;47:788–92.
105. Muccioli L, Farolfi A, Pondrelli F, d'Orsi G, Michelucci R, Freri E, et al. FDG-PET assessment and metabolic patterns in Lafora disease. *Eur J Nucl Med Mol Imaging*. 2020;47:1576–84.
106. Serratosa JM, Delgado-Escueta AV, Posada I, Shih S, Drury I, Berciano J, et al. The gene for progressive myoclonus epilepsy of the Lafora type maps to chromosome 6q. *Hum Mol Genet*. 1995;4:1657–63.
107. Carpenter S, Karpati G. Sweat gland duct cells in Lafora disease: diagnosis by skin biopsy. *Neurology*. 1981;31:1564–8.
108. Nita DA, Mole SE, Minassian BA. Neuronal ceroid lipofuscinoses. *Epileptic Disord*. 2016;1(18):73–88.
109. Mole SE, Williams RE. Neuronal ceroid-lipofuscinoses – retired chapter, for historical reference only. In: Adam MP, Ardinger HH, Pagon RA, Wallace SE, Bean LJH, Stephens K, et al. *GeneReviews* [Internet]. Seattle, WA: University of Washington; 2013. [cited 2022 Apr 9]. Available from: <https://www.ncbi.nlm.nih.gov/books/NBK1428/>
110. Moore SJ, Buckley DJ, MacMillan A, Marshall HD, Steele L, Ray PN, et al. The clinical and genetic epidemiology of neuronal ceroid lipofuscinosis in Newfoundland. *Clin Genet*. 2008;74:213–22.
111. Santorelli FM, Garavaglia B, Cardona F, Nardocci N, Bernardina BD, Sartori S, et al. Molecular epidemiology of childhood neuronal ceroid-lipofuscinosis in Italy. *Orphanet J Rare Dis*. 2013;2(8):19.
112. Specchio N, Bellusci M, Pietrafusa N, Trivisano M, de Palma L, Vigeveno F. Photosensitivity is an early marker of neuronal ceroid lipofuscinosis type 2 disease. *Epilepsia*. 2017;58:1380–8.
113. Schulz A, Ajayi T, Specchio N, de Los Reyes E, Gissen P, Ballon D, et al. Study of intraventricular cerliponase alfa for CLN2 disease. *N Engl J Med*. 2018;17(378):1898–907.
114. Boustany RM. Neurology of the neuronal ceroid-lipofuscinoses: late infantile and juvenile types. *Am J Med Genet*. 1992;15(42):533–5.
115. Kitzmüller C, Haines RL, Codlin S, Cutler DF, Mole SE. A function retained by the common mutant CLN3 protein is responsible for the late onset of juvenile neuronal ceroid lipofuscinosis. *Hum Mol Genet*. 2008;15(17):303–12.
116. Berkovic SF, Carpenter S, Andermann F, Andermann E, Wolfe LS. Kufs' disease: a critical reappraisal. *Brain*. 1988;111(Pt 1):27–62.
117. Arsov T, Smith K, Damiano J, Franceschetti S, Canafoglia L, Bromhead C, et al. Kufs disease, the major adult form of neuronal ceroid lipofuscinosis, caused by mutations in CLN6. *Am J Hum Genet*. 2011;13(88):566–73.
118. Tatum WO, Hirsch LJ, Gelfand MA, Acton EK, LaFrance WC, Duckrow RB, et al. Assessment of the predictive value of outpatient smartphone videos for diagnosis of epileptic seizures. *JAMA Neurol*. 2020;1(77):593–600.
119. Steriade C, Britton J, Dale RC, Gadoth A, Irani SR, Linnoila J, et al. Acute symptomatic seizures secondary to autoimmune encephalitis and autoimmune-associated epilepsy: conceptual definitions. *Epilepsia*. 2020;61:1341–51.
120. Kotulska K, Kwiatkowski DJ, Curatolo P, Weschke B, Riney K, Jansen F, et al. Prevention of epilepsy in infants with tuberous sclerosis complex in the EPISTOP trial. *Ann Neurol*. 2021;89:304–14.

**How to cite this article:** Riney K, Bogacz A, Somerville E, Hirsch E, Nabbout R, Scheffer IE, et al. International League Against Epilepsy classification and definition of epilepsy syndromes with onset at a variable age: position statement by the ILAE Task Force on Nosology and Definitions. *Epilepsia*. 2022;63:1443–1474. <https://doi.org/10.1111/epi.17240>