



DOI: 10.32768/abc.2022593401-406



Oncological Mastectomy in the Context of Reaffirmation of Sex in a Male Transgender Patient: Case Report and Literature Review

 Pablo Sciuto^a, Lucía Romero^a, Andrea Cristiani^b, Daniel González^a
^a*Surgical Clinic "3", University of the Republic, Montevideo, Uruguay*
^b*Pathological Anatomy Chair, University of the Republic, Montevideo, Uruguay*

ARTICLE INFO

Received:

25 January 2022

Revised:

06 April 2022

Accepted:

06 April 2022

Keywords:
 Cancer-related fatigue,
 male transgender,
 reaffirmation mastectomy

ABSTRACT

Background: Breast cancer in the male transgender patient is a great challenge for the medical team, because it is completely different from the usual clinical scenario and there is a lack of scientific knowledge and protocols for managing this special medical situation.

Case presentation: We present a 32-year-old transmasculine patient, who developed a palpable nodule on the left breast during the androgen hormonal treatment. Imaging showed a BIRADS5 nodule and core biopsy detected a luminal B breast invasive carcinoma (IDC) with androgen receptor expression. He underwent a gender reaffirmation oncological mastectomy, chemotherapy and hormonal therapy.

Conclusion: In the transgender male scenario, the surgical technique should take into consideration the patient's aesthetic desire and the oncological result. In this context, it is controversial if the hormonal and oncological therapies should also be changed.

Copyright © 2022. This is an open-access article distributed under the terms of the [Creative Commons Attribution-Non-Commercial 4.0 International License](https://creativecommons.org/licenses/by-nc/4.0/), which permits copy and redistribution of the material in any medium or format or adapt, remix, transform, and build upon the material for any purpose, except for commercial purposes.

INTRODUCTION

A transgender man is a biological female that identifies herself as a male. There are between 8 and 25 million transgender people in the world. In the United States there are 1.5 million transgender people, and this figure is increasing every year.^{1,2} In Uruguay in 2016, there were 853 transgender people, 10% of whom were transgender men. In our country, there are around 1900 new cases per year. There are no records of breast cancer in transgender people.

The increase in the transgender population reveals the necessity to modify the classical approach for cis women to satisfy the special requirements involved.

CASE REPORT

The patient was a 32-year-old trans male patient who initiated a treatment with testosterone 5mg per day for 45 days before consulting. Family records were

unavailable. He had a 3cm hard lump in the 4 o'clock radius of left breast and no palpable lymph nodes. Ultrasound, mammography and breast magnetic nuclear resonance (MRI) (Figure 1) reported a BIRADS5 nodule with normal axilla.

Core biopsy showed an infiltrating ductal carcinoma (IDC), final histological grade II, positive estrogen receptor (ER), negative progesterone receptors (PR), positive HER 2 neu (FISH amplified) and Ki67 70%.

To achieve the patient's aesthetic desires, bilateral total mastectomy with a free graft of the nipple areolar complex (NAC) and a sentinel node biopsy were performed without any incidents.

In the frozen section, we evaluated 4 sentinel lymph node that were negative. The patient had good immediate post-operative evolution (Figure 2).

Drains were removed on the 6th postoperative day. As a complication, he presented necrosis of the left nipple areolar complex (NAC) graft.

***Address for correspondence:**
 Pablo Sciuto, MD
 Surgical Clinic "3" University of the Republic, Montevideo,
 Uruguay
 Tel: +59829153000
 Email: sciutopablo@hotmail.com

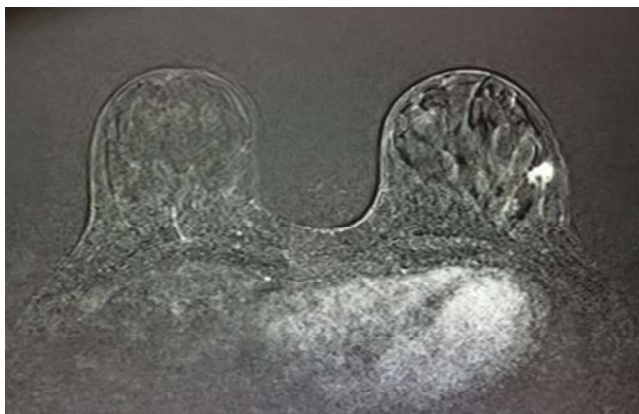


Figure 1. Axial DCE-MRI subtracted image. There is an irregular enhancement in distal 4 o'clock radius of the left breast that was confirmed as carcinoma by biopsy. There are no other pathological images in this or the contralateral breast.

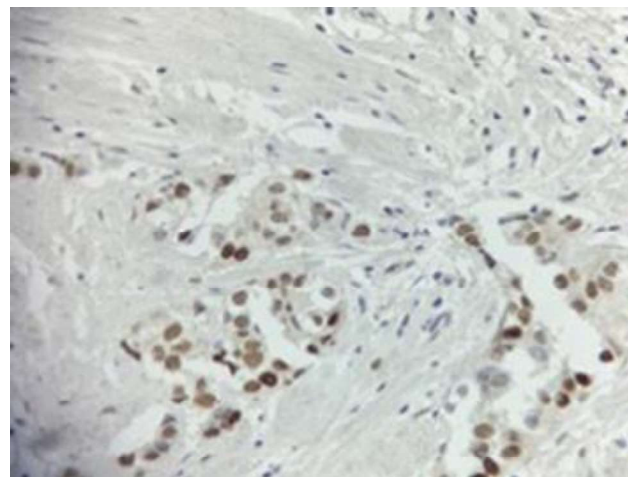


Figure 3. Androgen Receptor immunohistochemistry showing nuclear positivity in the invasive tumor.

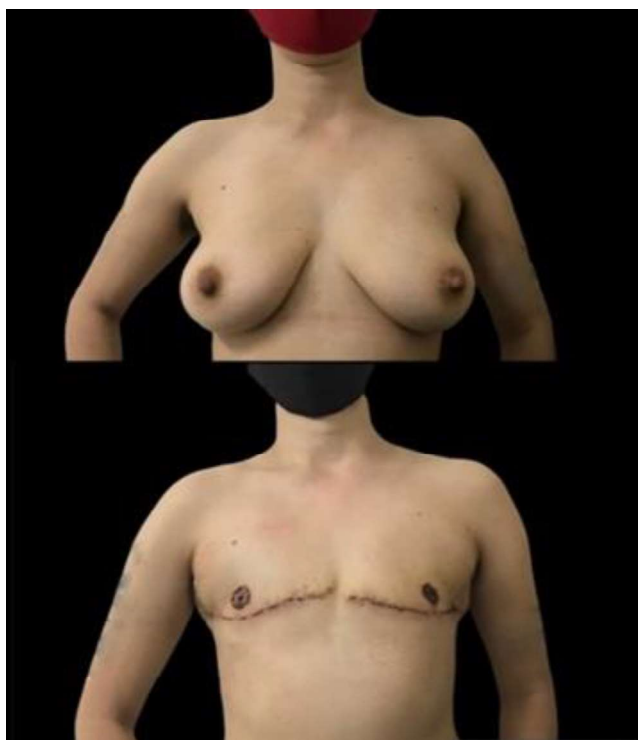


Figure 2. Before (A) and after (B) oncological mastectomy with a NAC free graft.

The final pathological report showed IDC (score 9), final histological grade 3 and 1% of high grade in situ ductal carcinoma (DCIS) with free margins, lymphatic emboli present. The 4 lymph nodes were negative. pT1c N0sn. Androgen receptors (RA) were positive (Figure 3).

He received adriamycin and cyclophosphamide x 4, paclitaxel weekly for 12 weeks plus Trastuzumab and Tamoxifen. There was no indication for radiotherapy. After discussing with the patient and the transgender health team, we decided to continue the testosterone treatment for gender reaffirmation.

DISCUSSION

Breast cancer is the most common cancer in biological female, but its incidence in transgender men remains unknown. Treating breast cancer in transgender patients is a completely different scenario than treating a cis woman, and as the transgender population increases, understanding it becomes essential, as mentioned by the World Professional Association for Transgender Health (WPATH).³

Besides the classical risk factors, in trans male patients we must also consider at least two different situations.⁴ Firstly, we must consider the hormonal treatment for masculinization, because there is contradictive evidence about its proliferative effect in the mammary gland. Secondly, we must address the risk reduction effect of sex affirming mastectomy.

In the literature, we found three population studies and five systematic reviews and case reports. Taking all the cases into account, there were only 24 cases of breast cancer in transgender men by 2020.³⁻¹¹

It is important to emphasize that these papers show a substantial heterogeneity regarding histological diagnosis (DCIS, IDC and grade), biological profile (ER, PR, HER2 neu, AR), stage and sequence between the appearance of breast cancer and mastectomy. These is an important bias for an incidence analysis (Table 1). Available data show that the incidence of breast cancer in transgender men is significantly lower than that in general population.

Most authors attribute this lower risk to the low levels of estrogens induced by testosterone therapy added to the risk-reducing effect of mastectomies.

Subcutaneous mastectomy implies a risk reduction of around 90%, but this depends on how much glandular tissue is preserved. Therefore, transferring these findings to a sex affirming mastectomy surgery that leaves a higher percentage of glandular tissue is not possible.¹²

**Table 1.** Cases of Female-to-Male transsexuals developing breast cancer after testosterone therapy

Author	Study Design	Age (in years) at diagnosis	Mastectomy prior to diagnosis	Family history	Testosterone use in years	Tumor type	BRCA status	Receptor status
Burcombe <i>et al.</i> (2003)	Case report	33	Yes (10 years after mastectomy)	Negative	13	Ductal Carcinoma	Unknown	ER+, PR+
Shao <i>et al.</i> (2011)	Case report	27	No*	Positive	6	Invasive ductal carcinoma grade 3	Negative	ER+, PR+, HER2+
Shao <i>et al.</i> (2011)	Case report	53	No*	Positive	5	Invasive ductal carcinoma grade 2	Negative	ER+, PR, HER2+
Nikolic <i>et al.</i> (2012)	Case report	42	Yes (1 years after mastectomy)	Negative	2.5	Invasive ductal carcinoma	Not Tested	ER-, PR-, AR+, HER2+
Gooren <i>et al.</i> (2013)	Retrospective cohort study	27	Yes, incidental finding	Unknown	3	Tubular adenocarcinoma	Unknown	ER+, PR+
Brown & Jones (2015)	Retrospective cohort study	77	Unknown	Unknown	11	Unknown	Unknown	ER+, PR-
Gooren <i>et al.</i> (2015)	Case report	41	Yes, incidental finding	Unknown	1	Tubular adenocarcinoma	Unknown	ER+, PR+, HER2-
Gooren <i>et al.</i> (2015)	Case report	48	Yes	Unknown	9	Infiltrative ductal carcinoma	Unknown	ER-, PR-, HER2-
Katayama <i>et al.</i> (2016)	Case report	41	Yes (12 years after mastectomy)	Negative	15	Invasive ductal carcinoma	Unknown	ER+, PR+, HER2-
Barghouthi <i>et al.</i> (2018)	Case report	28	No	Paternal great grandmother with breast cancer, maternal great grandmother with ovarian cancer.	1	Invasive ductal carcinoma grade 3	Negative	ER-, PR-, AR-, HER2+
Treskova <i>et al.</i> (2018)	Case report	58	Yes, incidental finding	Unknown	25	Invasive ductal carcinoma	Unknown	ER+, PR-, HER2-
Van Renterghem <i>et al.</i> (2018)	Retrospective cohort study	31	Yes, incidental finding	Negative	1.3	Moderately differentiated invasive carcinoma	Unknown	ER+, PR+, HER2-
Chotai <i>et al.</i> (2019)	Case report	58	Yes (20 years after mastectomy)	Positive	10	Invasive ductal carcinoma grade 3	Unknown	ER+, PR+, HER2+
De Blok <i>et al.</i> (2019)	Retrospective	30-50 (n=2),	Yes (n=3) ("several years after	Unknown	Median 15; range 2-17	Ductal origin (n=3)	Unknown	ER+ (n=2), PR+



Author	Study Design	Age (in years) at diagnosis	Mastectomy prior to diagnosis	Family history	Testosterone use in years	Tumor type	BRCA status	Receptor status
Describes four cases (n = 4)	cohort study	>50 (n=2)	mastectomy”) and Yes, incidental finding (n=1)					(n=2), HER2+ (n=1), AR+ (n=1)
Eismann <i>et al.</i> (2019) and Baker <i>et al.</i> (2019)	Case report and retrospective cohort study	29	Yes, incidental finding	Positive	4	High-grade DCIS	Negative	ER+
Fundytyus <i>et al.</i> (2019)	Case report	48	Yes, incidental finding	Positive	19	Invasive ductal carcinoma	Unknown	ER+, PR+, AR+, HER2-
Tanini <i>et al.</i> (2019)	Case report	33	Yes, incidental finding	Positive	2.5	DCIS grade 3	Unknown	ER+, PR+, AR+
Tanini <i>et al.</i> (2019)	Case report	36	No	Positive	3	Poorly differentiated invasive carcinoma of no special type	Negative	ER+, PR+, HER2+, AR+ (60%)
Light <i>et al.</i> (2020)	Case report	44	No*	Unknown, due to adoption	4 months	Invasive ductal carcinoma grade 2	Unknown	ER+, PR+, AR+, HER2-
Fledderus <i>et al.</i> (2020)	Case report	50	Yes, incidental finding	Positive	3	DCIS	Not Tested	Not Tested
Sciuto <i>et al.</i> (2021) (current article)	Case report	31	No	Unknown, due to adoption	1,5 month	DCIS	Negative	ER+, PR-, AR+, HER2+

We have not found cases where the patient has been diagnosed with breast cancer at the beginning of his hormonal treatment and wanted a sex affirming mastectomy. Given the size of the breasts, we opted for a mastectomy with a NAC free graft, plus a sentinel node biopsy to achieve oncologically effective treatment and masculinization of the torso. It was very important to preserve a flap thickness that ensured viability without leaving too much glandular tissue, especially in the tale of Spence.

In this context, ensuring free margins and a complete removal of the gland was a priority. Other key points were converting the submammary groove into a submuscular groove, not leaving dog ears and finally relocating the areolar nipple complex.¹³⁻¹⁵

The patient had necrosis of the left PDA graft in the pathological breast in the evolution, probably, due to the need for finer dermo-fat flaps, but despite this, the aesthetic result was satisfactory (Figure 5).

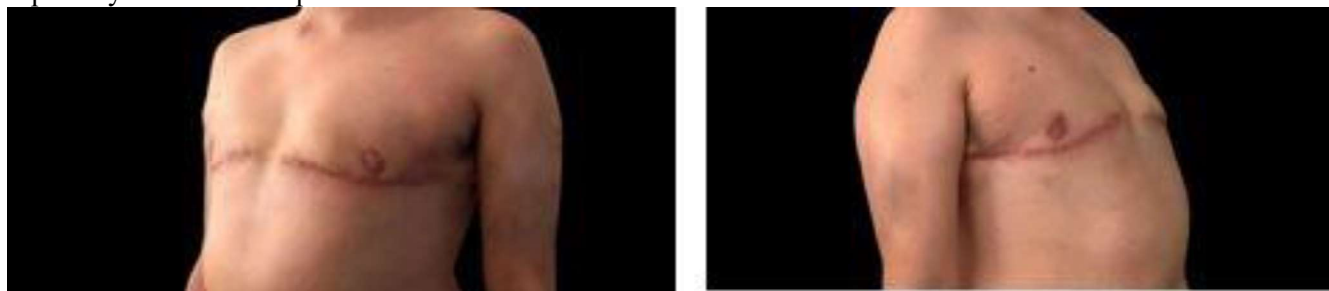


Figure 5. 2 months after oncological mastectomy with CAP-free graft.



Finally, the data about the role of androgens in the development of breast cancer are conflicting and there are no data about the effect of androgens on AR positive breast cancer, so the best adjuvant endocrine therapy is not known. Also, 72% of all breast cancers express androgen receptor and it is generally considered a good prognostic factor, especially in luminal tumors, but none of these aspects has been analyzed in the context of androgen hormone therapy.¹⁶

Some authors recommend stopping androgen therapy, but this can contradict the patient's will. Regarding the peripheral androgen-to-estrogen conversion, some authors recommend aromatase inhibitors and others lowering the androgen dose or switching to dihydrotestosterone, which is non-aromatizable.^{11,12,17}

Taking this into consideration, the detection of AR should become a standard for this population, although the effects of stimulating or blocking the AR are unknown, and even less frequently observed, in an androgen therapy context.

REFERENCES

1. Winter S, Diamond M, Green J, Karasic D, Reed T, Whittle S, et al. Transgender people: health at the margins of society. *The Lancet*. 2016;388(10042):390-400. doi: 10.1016/s0140-6736(16)00683-8.
2. Flores A, Herman J, Gates G, Brown T. How Many Adults Identify as Transgender in the United States?. 2016. Available from: <https://williamsinstitute.law.ucla.edu/wp-content/uploads/Trans-Adults-US-Aug-2016.pdf>
3. Coleman E, Bockting W, Botzer M, Cohen-Kettenis P, DeCuypere G, Feldman J, et al. Standards of Care for the Health of Transsexual, Transgender, and Gender-Nonconforming People, Version 7. *International Journal of Transgenderism*. 2012;13(4):165-232. doi: 10.1080/15532739.2011.700873.
4. Brettes JP MC. Dual effects of androgens on mammary gland. *Bull Cancer*. 2008;95:495-502. doi: 10.1684/bdc.2008.0631.
5. Gooren LJ, van Trotsenburg MA, Giltay EJ, van Diest PJ. Breast cancer development in transsexual subjects receiving cross-sex hormone treatment. *J Sex Med*. 2013 Dec;10(12):3129-34. doi: 10.1111/jsm.12319.
6. Brown GR, Jones KT. Incidence of breast cancer in a cohort of 5,135 transgender veterans. *Breast Cancer Res Treat*. 2015;149(1):191-8. doi: 10.1007/s10549-014-3213-2.
7. de Blok CJM, Wiepjes CM, Nota NM, van Engelen K, Adank MA, Dreijerink KMA, et al. Breast cancer risk in transgender people receiving hormone treatment: nationwide cohort study in the Netherlands. *Bmj*. 2019;365:l1652. doi: 10.1136/bmj.l1652.
8. Stone JP, Hartley RL, Temple-Oberle C. Breast cancer in transgender patients: A systematic review. Part 2: Female to Male. *Eur J Surg Oncol*. 2018;44(10):1463-8. doi: 10.1016/j.ejso.2018.06.021.
9. Joint R, Chen ZE, Cameron S. Breast and reproductive cancers in the transgender population: a systematic review. *Bjog*. 2018;125(12):1505-12. doi: 10.1111/1471-0528.15258.
10. Eismann J, Heng YJ, Fleischmann-Rose K, Tobias AM, Phillips J, Wulf GM, et al. Interdisciplinary Management of Transgender Individuals at Risk for Breast Cancer: Case Reports and Review of the Literature. *Clin Breast Cancer*. 2019;19(1):e12-e9. doi: 10.1016/j.clbc.2018.11.007.
11. Kopetti C, Schaffer C, Zaman K, Liapi A, di Summa PG, Bauquis O. Invasive Breast Cancer in a Trans Man After Bilateral Mastectomy: Case Report and Literature Review. *Clin Breast Cancer*. 2021;21(3):e154-e7. doi: 10.1016/j.clbc.2020.10.005.
12. Alaofi RK, Nassif MO, Al-Hajeili MR. Prophylactic mastectomy for the prevention of breast cancer: Review of the literature. *Avicenna J Med*. 2018;8(3):67-77. doi: 10.4103/ajm.AJM_21_18.
13. Gooren L, Bowers M, Lips P, Konings IR. Five new cases of breast cancer in transsexual persons. *Andrologia*. 2015;47(10):1202-5. doi: 10.1111/and.12399.
14. Burcombe RJ, Makris A, Pittam M, Finer N. Breast cancer after bilateral subcutaneous mastectomy in a female-to-male trans-sexual. *Breast*. 2003;12(4):290-3. doi: 10.1016/s0960-9776(03)00033-x.
15. Wolf Y, Kwartin S. Classification of Transgender Man's Breast for Optimizing Chest Masculinizing Gender-affirming Surgery. *Plast Reconstr Surg Glob Open*. 2021;9(1):e3363. doi: 10.1097/gox.00000000000003363.

CONCLUSION

This article makes a contribution to the scarce literature on a sensitive topic that affects a socially vulnerable population that is growing by raising awareness about this problem, with the hope that protocols or treatment guidelines are developed to provide quality care to this population.

ETHICAL CONSIDERATIONS

The patient signed up an informed consent to publish his information and images within this case report.

ACKNOWLEDGEMENTS

None.

CONFLICT OF INTEREST

The authors declare that they have no conflict of interests related to the publication of this manuscript.



16. Hickey TE, Selth LA, Chia KM, Laven-Law G, Milioli HH, Roden D, et al. The androgen receptor is a tumor suppressor in estrogen receptor-positive breast cancer. *Nat Med.* 2021;27(2):310-20. doi: 10.1038/s41591-020-01168-7.
17. Fledderus AC, Gout HA, Ogilvie AC, van Loenen DKG. Breast malignancy in female-to-male transsexuals: systematic review, case report, and recommendations for screening. *Breast.* 2020;53:92-100. doi: 10.1016/j.breast.2020.06.008.

How to Cite This Article

Sciuto P, Romero L, Cristiani A, González D. Oncological Mastectomy in the Context of Reaffirmation of Sex in a Male Transgender Patient: Case Report and Literature Review. Arch Breast Cancer. 2022; 9(3): 401-406.

Available from: <https://www.archbreastcancer.com/index.php/abc/article/view/566>