



# Two mutations in the *SBDS* gene reveal a diagnosis of Shwachman–Diamond syndrome in a patient with atypical symptoms

María Noel Spangenberg,<sup>1</sup> Sofia Grille,<sup>1,2</sup> Camila Simoes,<sup>2,3</sup> Nicolás Dell’Oca,<sup>4</sup> Matilde Boada,<sup>1</sup> Cecilia Guillermo,<sup>1</sup> Victor Raggio,<sup>4</sup> and Lucía Spangenberg<sup>2,3</sup>

<sup>1</sup>Departamento de Hematología, <sup>2</sup>Departamento Básico de Medicina, Hospital de Clínicas, Facultad de Medicina, Universidad de la República, 11600 Montevideo, Uruguay; <sup>3</sup>Bioinformatics Unit, Institut Pasteur de Montevideo, 11400 Montevideo, Uruguay; <sup>4</sup>Departamento de Genética, Facultad de Medicina, Universidad de la República, 11800 Montevideo, Uruguay

**Abstract** We present the case of a 53-yr-old woman with an inherited bone marrow failure coexisting with uncommon extrahematological symptoms, such as cirrhosis and skin abnormalities. Whole-exome sequencing revealed a diagnosis of Shwachman–Diamond syndrome (SDS) with an atypical presentation. Unexpected was the age of disease expression, normally around the pediatric age, with a predominantly median survival age of 36 yr. To our knowledge, she was the first adult patient with a molecular diagnosis of Shwachman–Diamond in Uruguay. The patient was referred to our service when she was 43-yr-old with a history of bone marrow failure with anemia and thrombocytopenia. All secondary causes of pancytopenia were excluded. Bone marrow aspirate and biopsy specimens were hypocellular for the patient’s age. Numerous dysplastic features were observed in the three lineages. She had a normal karyotype and normal chromosomal fragility. A diagnosis of low-risk hypoplastic MDS was made. Dermatological examination revealed reticulate skin pigmentation with hypopigmented macules involving the face, neck, and extremities; nail dystrophy; premature graying; and thin hair. Extrahematological manifestations were present (e.g., learning difficulties, short stature). Last, she was diagnosed with cryptogenic liver cirrhosis CHILD C. This rules out all other possible causes of chronic liver disease. This clinical presentation initially oriented the diagnosis toward telomeropathy, so we did a telomeropathy NGS panel that came up negative. Finally, we did an exome sequencing that confirmed the diagnosis of SDS. Using whole-exome sequencing, we were able to find two compound heterozygous mutations in the *SBDS* gene that were responsible for the phenotype of a patient that was undiagnosed for 10 years. An earlier genetic diagnosis could have influenced our patient’s outcome.

Corresponding author:  
lucia@pasteur.edu.uy

© 2022 Spangenberg et al. This article is distributed under the terms of the Creative Commons Attribution-NonCommercial License, which permits reuse and redistribution, except for commercial purposes, provided that the original author and source are credited.

**Ontology terms:** bone marrow hypocellularity; hematological neoplasm; multiple lineage myelodysplasia

Published by Cold Spring Harbor Laboratory Press

doi:10.1101/mcs.a006237

[Supplemental material is available for this article.]

## INTRODUCTION

Shwachman–Diamond syndrome (SDS) is a rare, multisystem, autosomal, recessively inherited disorder that has a wide variety of abnormalities and heterogeneous symptoms (Shwachman et al. 1964), making it difficult to diagnose in many cases.

SDS is clinically characterized by exocrine pancreatic dysfunction, bony metaphyseal dysostosis, and varying degrees of bone marrow failure. According to a recent study, the

cumulative incidence of severe neutropenia, thrombocytopenia, and anemia at the age of 30 yr is 59.9%, 66.8%, and 20.2%, respectively. The 20-yr cumulative incidence of myelodysplastic syndrome and/or leukemia is 9.8% (Cesaro et al. 2020). The 20-yr cumulative risk of bone marrow failure and/or severe cytopenia ranges from 9.9% to 24.3%, according to different studies (Donadieu et al. 2012; Cesaro et al. 2020). Severe marrow failure with transplant requirement was developed in ~5% of patients at a median age of 1.7 yr, according to a different study (Furutani et al. 2022). The probability of overall survival at 10 and 20 yr was 95.7% and 87.4%, respectively (Cesaro et al. 2020). More rarely, it can cause chronic diarrhea (Alshammari et al. 2021), it can be associated with features mimicking common variable immunodeficiency (Hou 2021), and there is one case report associating it with cirrhosis in a child (Camacho et al. 2019).

In patients with SDS, Boocock et al. (2003) identified mutations in a previously uncharacterized gene, which was then designated as *SBDS* (Shwachman–Diamond–Bodian syndrome). In that study, 56% of the patients harbored two compound heterozygous mutations in exon 2 of the *SBDS* gene; namely, the c.183-184TA-CT (K62X) stopgain and 258+2T-C in the splicing site. Subsequent studies identified that biallelic mutations in the *SBDS* gene account for >90% of SDS cases (Nakashima et al. 2004; Kuijpers et al. 2005; Cesaro et al. 2020; Yamada et al. 2020; Furutani et al. 2022). However, additional genes such as *EFL1*, *DNAJC21*, and *SRP54* may also be involved in SDS (Carapito et al. 2017; Dhanraj et al. 2017).

The *SBDS* gene encodes for a highly conserved protein that plays an essential role in ribosome biogenesis. The protein interacts with elongation factor-like GTPase 1 (*EFL1*) to dissociate eukaryotic initiation factor 6 (*eIF6*) from the late cytoplasmic pre-60S ribosomal subunit, allowing the assembly of the 80S subunit by a mechanism requiring GTP binding and hydrolysis (Finch et al. 2011)

The advent of high-throughput sequencing techniques has substantially improved diagnosis of rare diseases, increasing the diagnostic yield, depending on the pathology and genomic strategy (WES [whole-exome sequencing] and WGS [whole-genome sequencing or gene panels]) to 36%–50% (Gilissen et al. 2014; Trujillano et al. 2017; Palmer et al. 2021; Álvarez-Mora et al. 2022). WES and WGS are especially useful in diseases whose etiology is unknown, that are associated with mutations in various genes, or that have atypical presentations and/or a wide spectrum of symptoms associated with them, as well as in cases in which gene panels or other genomic strategies were already done and came up “negative.” In the present case, the patient had an atypical presentation of the Shwachman–Diamond syndrome with cirrhosis and atypical cutaneous manifestations that standard clinical and genomic studies (gene panel and karyotype) were unable to reach a diagnosis.

## RESULTS

---

### Case Report

Here, we report a 53-yr-old woman who has been treated at our Hematology Department at Dr. Manuel Quintela Hospital de Clínicas in Montevideo for 10 years. She has no family history of clinical relevance, and her parents were not consanguineous. She was referred to our service when she was 43 yr old with a history of bone marrow failure with anemia and thrombocytopenia. She had a blood count that showed hemoglobin level of ~9 g/dL, thrombocytopenia of  $70.0 \times 10^9/L$ , and neutropenia of  $0.9 \times 10^9/L$ . The blood smear showed marked anisocytosis, macrocytosis, and pseudo-Pelger–Huet anomaly on neutrophils. These values have been stable for years without the need of transfusion. Biochemical tests were all within normal range. Notably serum iron level and saturation of transferrin were normal, and serum ferritin was increased (270 ng/mL). There was no vitamin B12 deficiency or folic acid

deficiency. Serological tests for CMV, HIV, and hepatitis B and C were negative. Bone marrow aspirate and biopsy specimens showed 25% cellularity (hypocellular for patient age). Numerous dysplastic features were observed in the three lineages. The erythroid cells displayed marked dyserythropoietic changes: karyorrhexis, nuclear budding, internuclear bridging, megaloblastosis, and punctate basophilia. Granulopoiesis was often hypogranular. Increased blast and Auer rods were not observed. Abnormal thrombopoiesis was also present with an increased number of megakaryocytes with bilobed nuclei. Bone marrow biopsy detected an increase of reticulin fibrosis. Conventional cytogenetic analysis performed on bone marrow cells showed a normal karyotype (46,XX). Chromosomal fragility test was negative. Flow cytometric showed normal expression of GPI-linked proteins excluding paroxysmal nocturnal hemoglobinuria. A diagnosis of hypoplastic MDS was proposed, and the patient received treatment with cyclosporin A for several years, achieving partial response.

Several extrahematological manifestations were also present: learning difficulties, delays in reaching developmental milestones as a child, and short stature. As a child she required surgical intervention for coxovarus. During follow-up, dermatological examination revealed reticulate skin pigmentation with hypopigmented macules involving the face, neck and extremities; nail dystrophy; premature graying; and thin hair. Furthermore, the patient lost all dental pieces because of caries and gum pathologies. At the age of 53, she was diagnosed with cryptogenic liver cirrhosis CHILD C (Child and Turcotte 1964), meaning an advanced hepatic dysfunction. This rules out all other possible causes of chronic liver disease. We hypothesize that the liver dysfunction and probable exocrine pancreatic insufficiency may determine chronic vitamin A and zinc deficiency that could explain the skin symptoms.

In April 2021, she was admitted to the hospital because of neutropenic fever that progressed to sepsis and unfortunately died as a result of infection from Gram-negative multi-resistant bacteria. Neutropenia was severe,  $<200/\text{mm}^3$ , and bone marrow studies were repeated, excluding progression to AML.

Written informed consent for publication was obtained from the patient before her passing.

An inherited bone marrow syndrome was suspected since our first contact with the patient. However, at that time it was not feasible to carry out comprehensive genomic studies locally. Dyskeratosis congenita and/or telomeropathy were our primary clinical diagnosis. For that reason, we performed a telomeropathy-targeted NGS panel in an external laboratory including the genes *CTC1*, *DKC1*, *NHP2* (*NOLA2*), *NOP10* (*NOLA3*), *RTEL1*, *TERC*, *TERT*, *TINF2*, *USB1* (*C16ORF57*), and *WRAP53*, but no pathogenic/causative variant was identified. We were not able to measure the length of the telomeres in our country at that time.

### Whole-Exome Sequencing and Bioinformatic Analysis

We performed exome sequencing in the setting of a local pilot program aimed at promoting the use of massive sequencing in the diagnosis of rare genetic diseases. We found two compound heterozygous mutations in the *SBDS* gene that we believe are causative of the patient's clinical features.

The first mutation is an already described stopgain mutation (NM\_016038:exon2:c.A184T;p.K62X ClinVar Variation ID 3195).

The premature stop codon is in the second exon at position 62 of a 251-amino-acid-long protein and hence in the first ~25% of the gene product. According to gnomAD, the overall variant's population frequency is 0.00026. The second mutation is an already described splicing one, affecting the adenine in the canonical donor site of the second exon (NM\_016038:exon3:c.258 + 2T > C, ClinVar Variation ID 3196) (Table 1). The overall variant's population frequency is 0.0039. The co-occurrence of both variants is rare in the general

**Table 1.** Variant table

Gene	Chromosome	HGVS DNA reference	HGVS protein reference	Variant type	Predicted effect	dbSNP/dbVar ID	Genotype	Comments
SBDS	7	c.A184T	p.K62X	Exonic	Stopgain	NA	Het	Predicted as pathogenic in compound heterozygosity with the other variant. OMIM phenotype 607444
SBDS	7	c.258 + 2T > C	NA	Noncoding	Splicing	rs113993993	Het	Predicted as pathogenic in compound heterozygosity with the other variant. OMIM phenotype 607444

population (but are fairly common among the patients with this phenotype), corresponding to a rare phenotype, as the one she presents. The syndrome associated with this gene is Shwachman–Diamond syndrome, with MIM #260,400, and it has an estimated frequency of one in 80,000 newborns (<https://medlineplus.gov/>).

## DISCUSSION

We present the case of a 53-yr-old woman with inherited bone marrow failure (IBMF) coexisting with uncommon extrahematological signs, such as cirrhosis and skin abnormalities. Genomic studies revealed a diagnosis of Shwachman–Diamond syndrome with atypical presentation, highlighting the fact that the usual age of diagnosis is in the pediatric age (before the age of 1 yr), with a predominantly median survival age of >35 yr (Hall et al. 2006). However, patients with significant hematological complications have a reduced life expectancy (Hall et al. 2006). To our knowledge, she was among the first adult patients with a molecular diagnosis of Shwachman–Diamond in our country.

IBMF syndromes are highly heterogeneous. The clinical phenotypes are variable, often mild, do not always fully conform to classic syndromes, and largely overlap one another; previous family history can be absent. In this context, predicting an individual genotype based on clinical data is challenging. In addition, some IBMF patients may carry more than one mutated gene. Therefore, a broad approach encompassing the various IBMF genes and WES is extremely useful to obtain an accurate genetic diagnosis in an appropriate time frame.

SBDS is required for mature ribosome assembly and ribosome genesis. SBDS in interaction with elongation factor like-1 (EFL1) triggers the release of eIF6 (eukaryotic initiation factor 6) from 60S preribosomes into the cytoplasm (Menne et al. 2007; Finch et al. 2011; Warren 2018) in a GTP-dependent mechanism. This activates the ribosomes for translation, because it allows 80S ribosome assembly and the recycling of eIF6 to the nucleus, where it is needed for the processing of 60S rRNA and subsequent nuclear export. SBDS increases the affinity for GTP over GDP for ELF1, functioning as a nucleotide exchange factor (GEF) (Menne et al. 2007).

Most SDS patients display the biallelic pathogenic variants c.183\_184TA > CT (K62X) and c.258+2T > C (C84fsX3) (Boocock et al. 2003). Less frequently, patients harbor nonsense and splicing mutations (as the case presented here), and also missense and small indels, among others. Most known SBDS mutations result in a drop in protein function that causes, when SBDS levels drop below a threshold, the clinical SDS phenotype (Spinetti et al. 2022). Because of the relevant role of SBDS for EFL1 activation (Menne et al. 2007), it would be expected that low amounts of SBDS may not be sufficient for the proper activation and

functioning of EFL1. Additionally, *SBDS* missense mutations have been shown to classify into two groups: those affecting the stability of the protein (corresponding to a more classic LoF mechanism), but also those that modify surface epitopes without altering the protein fold (Finch et al. 2011; Gijsbers et al. 2018; Spinetti et al. 2022). The impact that surface modifications may have on the function of *SBDS* is less studied. However, recent studies have shown that domain III of *SBDS* is crucial for the interaction with EFL1, considered essential for proper ribosome function (Spinetti et al. 2022).

Evidence has shown the association of liver disease with this phenotype, although rarely. This involvement can include different levels of liver manifestations, such as different forms of persistent chronic liver disease due to hepatic fibrosis, including, in some cases, cirrhosis (Liebman et al. 1979; Toiviainen-Salo et al. 2009; Richards et al. 2015; Camacho et al. 2019; Lawal et al. 2020). Abnormal transaminase levels were often detected in neonates, and these returned to normal with age. Although there is enough evidence throughout the literature establishing the involvement of the liver in SDS, including hepatomegaly, asymptomatic elevation of serum transaminase levels, mild cholestasis, fatty infiltration, and the presence of microcysts, there are few studies evidencing the presence of liver failure and cirrhosis. There is no clear genotype–phenotype relationship in liver involvement, irrespective of the *SBDS* mutation. Few studies report mutations in patients, mainly in noncirrhotic liver involvement (Brueton et al. 1977; Liebman et al. 1979; Revert Lázaro et al. 2006; Camacho et al. 2019). Although the study by Toiviainen et al. (2009) reports the mutations together with phenotypic metadata of 12 patients with liver complications, none of the included patients had cirrhosis.

The *SBDS* gene is located in a block of 305 kb that is duplicated (Boocock et al. 2003). The duplication is located 5.8 Mb distally and contains an unprocessed pseudogene copy of *SBDS* named *SBDSP*. The pseudogene transcript is 97% identical to *SBDS* but harbors deletions and changes that disrupt coding potential. The presence of pseudogenes implies additional complications of bioinformatic analysis, because reads might map onto two regions in the genome, impacting mapping accuracy and quality. Stringent mapping criteria should be applied (unique mapping reads, small number of mismatches per reads, etc.). This genomic composition might explain some reads without mutations mapping into the *SBDS* region analyzed and other artifacts seen in Figure 1.

Regarding the DNA source, for this case we used whole blood. Alternatively, buccal swabs or hair follicle samples could be used as a DNA source, especially for pediatric patients.

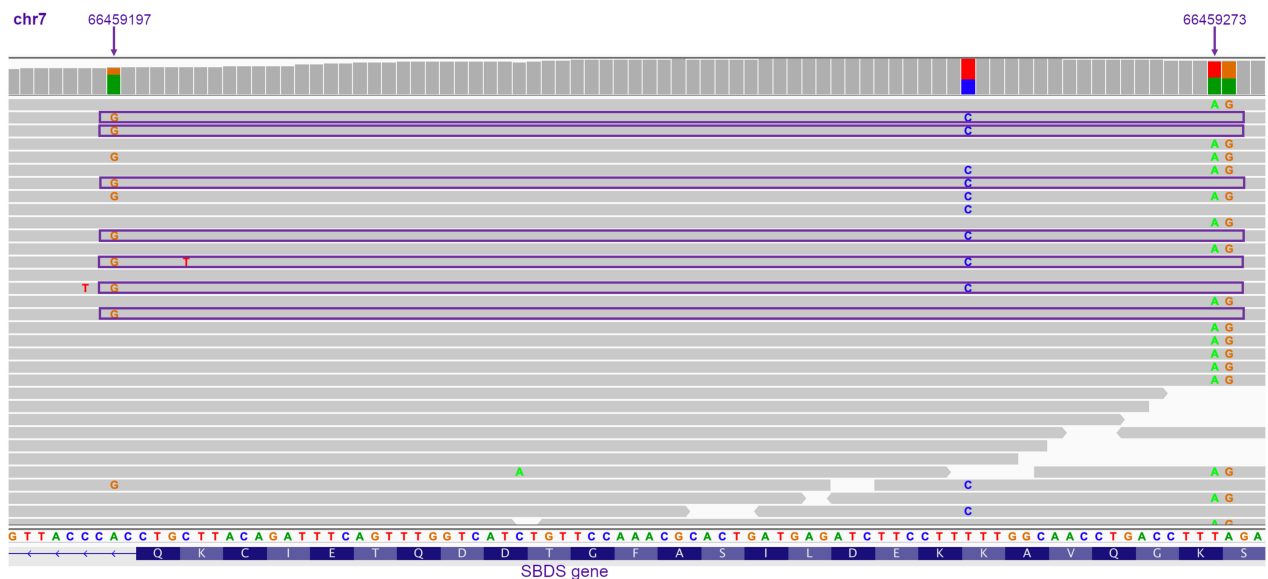
The patient was assisted in a pediatric hospital and referred to our center only at the age of 43 yr. The clinical presentation began in the pediatric age, because she had short stature, learning difficulties, delays in reaching developmental milestones as a child, and a history of cytopenias since childhood. This could have suggested SDS syndrome at that time, but because signs at pediatric age were nonspecific and the genetic tests were not easily available at that time in the country, the diagnosis ended up being very late. It might have been possible that having an early genetic diagnosis would have influenced our patient's outcome. Regarding hematological manifestations, allogeneic transplant would have been a feasible approach.

## METHODS

---

### Sample Extraction, Whole-Exome Sequencing, and Bioinformatic Analysis

Genomic DNA was extracted from 100  $\mu$ L of whole blood using Qiamp DNA Blood Mini kit according to the manufacturer's instructions. We did a whole-exome sequencing of the patient with 100 $\times$  in a HiSeq2500 Illumina sequencing machine.



**Figure 1.** Genomic view of the *SBDS* region using IGV (Integrative Genomic Viewer tool). Sequencing reads are represented as gray horizontal bars. The mutations in question are marked with arrows on top with their respective genomic positions. Mutations are explicitly indicated with the corresponding letter on the sequencing read. The vertical gray bars (on top) indicate the position's coverage. Reads marked with a violet horizontal box show the presence of G (at 66459197) and absence of A (at 66459273). These reads validate a *trans* configuration of both variants. The other two variants seen in the figure (C/T and G/A) were discarded as pathogenic because they are synonymous mutations. Also, one of them has a high population frequency (C/T).

FastQC (<https://www.bioinformatics.babraham.ac.uk/projects/fastqc/> accessed January 21, 2022; Wingett and Andrews 2018) was used for the quality of reads, and BWA (Li and Durbin 2009) was used for read mapping onto the human genome (GRCh37). Variant calling was undertaken using GATK (best practices) (McKenna et al. 2010). ANNOVAR (Wang et al. 2010) was used then for the annotation. Different sets of filters were used in order to detect potentially causative mutations (see below).

In order to filter and prioritize the variants found, we used the following criteria:

1. Homozygous mutations in coding/splicing region with a population frequency <1%.
2. Heterozygous mutations in coding/splicing region with at least two variants in the same gene and a population frequency <1% (compound heterozygous).
3. Heterozygous mutations in coding/splicing region with a population frequency <0.5%

Coverage table is available in Supplemental Table S1.

### Chromosome Fragility

The unique method called “chromosomal fragility testing” using clastogenic agents mitomycin C (MMC) and diepoxybutane (DEB) was described by Cervenka et al. (1981) and Auerbach (1993), respectively. The principle of this method is to challenge the hyposensitive cells in the cell culture (T-lymphocytes from peripheral blood) exposed to DEB and MMC and then to analyze the chromosomal aberration, breaks, and rearrangements (radials exchanges).

We did two cell cultures from peripheral blood with additional MMC at different concentrations: 150 and 300 nM. Two age- and sex-matched controls were performed at the same conditions. We evaluated 50 metaphases of each culture.

## ADDITIONAL INFORMATION

---

### Data Deposition and Access

The variants supporting the conclusions of this article are available in ClinVar repository (<https://www.ncbi.nlm.nih.gov/clinvar/>) under the identifiers VCV000003196.57 (stopgain) and VCV000003196.57 (splicing). Raw sequencing data was not deposited because of lack of patient consent.

### Ethics Statement

This research was performed in accordance with the Declaration of Helsinki and has been approved by the ethics committee of the Institut Pasteur de Montevideo on July 12, 2021, CEI-IP 002 2021. Informed consent to participate in the study was obtained from the participant and family.

### Author Contributions

S.G. and M.N.S. treated and followed the patient and wrote the manuscript. C.S. performed bioinformatic analysis of whole-exome data and reviewed the manuscript. M.B. and C.G. followed the patient in the hematological service and reviewed the manuscript. V.R. interpreted the variants and wrote the original draft of the manuscript. L.S. performed bioinformatic analysis, interpreted the variants, acquired funding, and wrote the original draft of the manuscript.

### Competing Interest Statement

The authors have declared no competing interest.

Received July 28, 2022; accepted in revised form October 10, 2022.

## REFERENCES

---

- Alshammari M, Aljohani MA, Hashash JM, Alsaedi HA, Alobaidi WY, Alhuzali NK, Alnumani MS, Alrashidi AH, Al-Battniji SA, Alotaibi NA, et al. 2021. Shwachman–Diamond syndrome in a child presenting with chronic diarrhea: a rare case in family medicine practice. *Cureus* **13**: e19391. doi:10.7759/cureus.19391
- Álvarez-Mora MI, Sánchez A, Rodríguez-Revenga L, Corominas J, Rabionet R, Puig S, Madrigal I. 2022. Diagnostic yield of next-generation sequencing in 87 families with neurodevelopmental disorders. *Orphanet J Rare Dis* **17**: 60. doi:10.1186/s13023-022-02213-z
- Auerbach AD. 1993. Fanconi anemia diagnosis and the diepoxybutane (DEB) test. *Exp Hematol* **21**: 731–733.
- Boocock GRB, Morrison JA, Popovic M, Richards N, Ellis L, Durie PR, Rommens JM. 2003. Mutations in *SBDS* are associated with Shwachman–Diamond syndrome. *Nat Genet* **33**: 97–101. doi:10.1038/ng1062
- Brueton MJ, Mavromichalis J, Goodchild MC, Anderson CM. 1977. Hepatic dysfunction in association with pancreatic insufficiency and cyclical neutropenia. Shwachman–Diamond syndrome. *Arch Dis Child* **52**: 76–78. doi:10.1136/adc.52.1.76
- Camacho SM, McLoughlin L, Nowicki MJ. 2019. Cirrhosis complicating Shwachman–Diamond syndrome: a case report. *World J Clin Cases* **7**: 1456–1460. doi:10.12998/wjcc.v7.i12.1456
- Carapito R, Konantz M, Paillard C, Miao Z, Pichot A, Leduc MS, Yang Y, Bergstrom KL, Mahoney DH, Shardy DL, et al. 2017. Mutations in signal recognition particle *SRP54* cause syndromic neutropenia with Shwachman–Diamond-like features. *J Clin Invest* **127**: 4090–4103. doi:10.1172/JCI92876
- Cervenka J, Arthur D, Yasis C. 1981. Mitomycin C test for diagnostic differentiation of idiopathic aplastic anemia and Fanconi anemia. *Pediatrics* **67**: 119–127. doi:10.1542/peds.67.1.119
- Cesaro S, Pegoraro A, Sainati L, Lucidi V, Montemitto E, Corti P, Ramenghi U, Nasi C, Menna G, Zecca M, et al. 2020. A prospective study of hematologic complications and long-term survival of Italian patients affected by Shwachman–Diamond syndrome. *J Pediatr* **219**: 196–201.e1. doi:10.1016/j.jpeds.2019.12.041
- Child CG, Turcotte JG. 1964. Surgery and portal hypertension. *Major Probl Clin Surg* **1**: 1–85.
- Dhanraj S, Matveev A, Li H, Lauhasurayotin S, Jardine L, Cada M, Zlateska B, Tailor CS, Zhou J, Mendoza-Londono R, et al. 2017. Biallelic mutations in *DNAJC21* cause Shwachman–Diamond syndrome. *Blood* **129**: 1557–1562. doi:10.1182/blood-2016-08-735431
- Donadieu J, Fenneteau O, Beaupain B, Beaufils S, Bellanger F, Mahlaoui N, Lambilliotte A, Aladjidi N, Bertrand Y, Mialou V, et al. 2012. Classification of and risk factors for hematologic complications in a French national cohort of 102 patients with Shwachman–Diamond syndrome. *Haematologica* **97**: 1312–1319. doi:10.3324/haematol.2011.057489

- Finch AJ, Hilcenko C, Basse N, Drynan LF, Goyenechea B, Menne TF, González Fernández A, Simpson P, D'Santos CS, Arends MJ, et al. 2011. Uncoupling of GTP hydrolysis from eIF6 release on the ribosome causes Shwachman–Diamond syndrome. *Genes Dev* **25**: 917–929. doi:10.1101/gad.623011
- Furutani E, Liu S, Galvin A, Steltz S, Malsch MM, Loveless SK, Mount L, Larson JH, Queenan K, Bertuch AA, et al. 2022. Hematologic complications with age in Shwachman–Diamond syndrome. *Blood Adv* **6**: 297–306. doi:10.1182/bloodadvances.2021005539
- Gijsbers A, Montagut DC, Méndez-Godoy A, Altamura D, Saviano M, Siliqi D, Sánchez-Puig N. 2018. Interaction of the GTPase elongation factor like-1 with the Shwachman–Diamond syndrome protein and its missense mutations. *Int J Mol Sci* **19**: 4012. doi:10.3390/ijms19124012
- Gilissen C, Hehir-Kwa JY, Thung DT, van de Vorst M, van Bon BW, Willemsen MH, Kwint M, Janssen IM, Hoischen A, Schenck A, et al. 2014. Genome sequencing identifies major causes of severe intellectual disability. *Nature* **511**: 344–347. doi:10.1038/nature13394
- Hall GW, Dale P, Dodge JA. 2006. Shwachman–Diamond syndrome: UK perspective. *Arch Dis Child* **91**: 521–524. doi:10.1136/adc.2003.046151
- Hou J-W. 2021. Shwachman–Diamond syndrome with initial features mimicking common variable immunodeficiency. *Pediatr Neonatol* **62**: 668–669. doi:10.1016/j.pedneo.2021.06.006
- Kuijpers TW, Alders M, Tool AT, Mellink C, Roos D, Hennekam RC. 2005. Hematologic abnormalities in Shwachman–Diamond syndrome: lack of genotype-phenotype relationship. *Blood* **106**: 356–361. doi:10.1182/blood-2004-11-4371
- Lawal OS, Mathur N, Eapi S, Chowdhury R, Malik BH. 2020. Liver and cardiac involvement in Shwachman–Diamond syndrome: a literature review. *Cureus* **12**: e6676. doi:10.7759/cureus.6676
- Li H, Durbin R. 2009. Fast and accurate short read alignment with Burrows–Wheeler transform. *Bioinformatics* **25**: 1754–1760. doi:10.1093/bioinformatics/btp324
- Liebman WM, Rosental E, Hirshberger M, Thaler MM. 1979. Shwachman–Diamond syndrome and chronic liver disease. *Clin Pediatr* **18**: 695–698. doi:10.1177/000992287901801106
- McKenna A, Hanna M, Banks E, Sivachenko A, Cibulskis K, Kernysky A, Garimella K, Altshuler D, Gabriel S, Daly M, et al. 2010. The Genome Analysis Toolkit: a MapReduce framework for analyzing next-generation DNA sequencing data. *Genome Res* **20**: 1297–1303. doi:10.1101/gr.107524.110
- Menne TF, Goyenechea B, Sánchez-Puig N, Wong CC, Tonkin LM, Ancliff PJ, Brost RL, Costanzo M, Boone C, Warren AJ. 2007. The Shwachman–Bodian–Diamond syndrome protein mediates translational activation of ribosomes in yeast. *Nat Genet* **39**: 486–495. doi:10.1038/ng1994
- Nakashima E, Mabuchi A, Makita Y, Masuno M, Ohashi H, Nishimura G, Ikegawa S. 2004. Novel SBDS mutations caused by gene conversion in Japanese patients with Shwachman–Diamond syndrome. *Hum Genet* **114**: 345–348. doi:10.1007/s00439-004-1081-2
- Palmer EE, Sachdev R, Macintosh R, Melo US, Mundlos S, Righetti S, Kandula T, Minoche AE, Puttick C, Gayevskiy V, et al. 2021. Diagnostic yield of whole genome sequencing after nondiagnostic exome sequencing or gene panel in developmental and epileptic encephalopathies. *Neurology* **96**: e1770–e1782. doi:10.1212/WNL.0000000000011655
- Revert Lázaro F, Pérez Monjardín E, Pérez AP. 2006. [Hypertransaminasemia as a manifestation of Shwachman–Diamond syndrome]. *An Pediatr* **64**: 481–484. doi:10.1157/13087877
- Richards S, Aziz N, Bale S, Bick D, Das S, Gastier-Foster J, Grody WW, Hegde M, Lyon E, Spector E, et al. 2015. Standards and guidelines for the interpretation of sequence variants: a joint consensus recommendation of the American College of Medical Genetics and Genomics and the Association for Molecular Pathology. *Genet Med* **17**: 405–424. doi:10.1038/gim.2015.30
- Shwachman H, Diamond LK, Oski FA, Khaw KT. 1964. The syndrome of pancreatic insufficiency and bone marrow dysfunction. *J Pediatr* **65**: 645–663. doi:10.1016/s0022-3476(64)80150-5
- Spinetti E, Delre P, Saviano M, Siliqi D, Lattanzi G, Mangiatordi GF. 2022. A comparative molecular dynamics study of selected point mutations in the Shwachman–Bodian–Diamond syndrome protein SBDS. *Int J Mol Sci* **23**: 7938. doi:10.3390/ijms23147938
- Toiviainen-Salo S, Durie PR, Numminen K, Heikkilä P, Marttinen E, Savilahti E, Mäkitie O. 2009. The natural history of Shwachman–Diamond syndrome-associated liver disease from childhood to adulthood. *J Pediatr* **155**: 807–811.e2. doi:10.1016/j.jpeds.2009.06.047
- Trujillano D, Bertoli-Avella AM, Kumar Kandaswamy K, Weiss ME, Köster J, Marais A, Paknia O, Schröder R, Garcia-Aznar JM, Werber M, et al. 2017. Clinical exome sequencing: results from 2819 samples reflecting 1000 families. *Eur J Hum Genet* **25**: 176–182. doi:10.1038/ejhg.2016.146
- Wang K, Li M, Hakonarson H. 2010. ANNOVAR: functional annotation of genetic variants from high-throughput sequencing data. *Nucl Acids Res* **38**: e164. doi:10.1093/nar/gkq603
- Warren AJ. 2018. Molecular basis of the human ribosomopathy Shwachman–Diamond syndrome. *Adv Biol Regul* **67**: 109–127. doi:10.1016/j.jbior.2017.09.002

- Wingett SW, Andrews S. 2018. FastQ Screen: a tool for multi-genome mapping and quality control. *F1000Res* **7**: 1338. doi:10.12688/f1000research.15931.1
- Yamada M, Uehara T, Suzuki H, Takenouchi T, Inui A, Ikemiyagi M, Kamimaki I, Kosaki K. 2020. Shortfall of exome analysis for diagnosis of Shwachman–Diamond syndrome: mismapping due to the pseudogene *SBDSP1*. *Am J Med Genet A* **182**: 1631–1636. doi:10.1002/ajmg.a.61598